



Cytomegalovirus Infection and Multiple Venous Thrombosis: A Rare Complication of a Common Infection

Gauthier Molls, Valérie Gangji and Muhammad S Soyfoo*

Department of Rheumatology, Erasmus Hospital, Université libre de Bruxelles (ULB), Brussels, Belgium

Abstract

Background: Cytomegalovirus (CMV) is a common cause of viral infection. In immunocompetent patients, CMV infection is usually mild or asymptomatic and does not require any treatment. However, in some patients systemic manifestations can occur.

Case Presentation: We report the case of a 40-year-old woman with a medical history of Graves' disease and papillomavirus infection presenting with swollen ankles associated with fever and pain in the lower limbs for several weeks. Clinical examination revealed bilateral induration of the calf. Laboratory tests showed elevated liver enzymes and systemic inflammation. Exploration by ultrasound of lower limbs and CT scan of the abdomen demonstrated superficial venous thrombosis of the lower limbs and thrombosis of the left hepatic vein. A thorough evaluation for hypercoagulability and septic states were negative. Finally, serological conversion for CMV was demonstrated with positive IgM and IgG with negative prior testing done seven years earlier. The patient was given an anticoagulation treatment and oral contraception was discontinued. The patient improved clinically and biologically after few weeks.

Conclusion: We describe a rare case of sub-acute CMV primary infection in an immunocompetent patient complicated with multiple thrombosis. This case illustrates a rare complication of a common infection in order to raise awareness of this entity.

Keywords: Thrombosis; Infection; CMV; Fever of unknown origin

OPEN ACCESS

*Correspondence:

Muhammad S Soyfoo, Department of Rheumatology, Erasmus Hospital, Université libre de Bruxelles (ULB), Brussels, Belgium, Tel: 003225553650; Fax: 003225558247;

E-mail: msoyfoo@ulb.ac.be

Received Date: 08 Aug 2017

Accepted Date: 25 Oct 2017

Published Date: 31 Oct 2017

Citation:

Molls G, Gangji V, Soyfoo MS. Cytomegalovirus Infection and Multiple Venous Thrombosis: A Rare Complication of a Common Infection. *Remed Open Access*. 2017; 2: 1082.

Copyright © 2017 Muhammad S Soyfoo. This is an open access article distributed under the Creative Commons Attribution License, which permits unrestricted use, distribution, and reproduction in any medium, provided the original work is properly cited.

Introduction

Acute cytomegalovirus (CMV) infection is a frequent infection both in immunocompetent and immunocompromised patients responsible of fever, fatigue, arthralgia, weight loss, and altered hepatic enzymes tests. The occurrence of thromboembolic events in the setting of acute CMV infection has been described but is a relatively scant finding.

Case Presentation

We report the case of a 40-year old Caucasian female patient initially admitted in the out-patient clinic of the rheumatology department for arthralgia, leg edema and vesperal fever since 5 weeks. Her past medical history included Graves's disease and dysplasia of the uterine cervix due to human papilloma virus. Her current medications were rosuvastatin 10 mg qid for hypercholesterolemia, levothyroxine 125 micrograms qid and oral contraceptive pill. The patient smoked 7 cigarettes per day and drank occasionally alcohol.

She had been well until 5 weeks earlier when she developed fever up to 39.5°C and arthralgia predominating in the ankles. The fever was essentially vesperal occurring in the late afternoons and at the beginning of the night. The patient did not report any skin eruptions accompanying fever nor night sweats. On physical examination, the left ankle was swollen and there was tenderness in both calves. The rest of the clinical examination was considered normal. The biological investigations yielded an increase in CRP levels (CRP 39 mg/L), increased γ GT (144 U/L (N: 5-36 U/L)) and alkaline phosphatase levels (107U/L (N: 42-98 U/L)) without increases in serum bilirubin levels. Blood hemocultures ruled out any bacterial infections. Conventional X-rays of the ankles were normal whilst lower limbs Doppler ultrasonography showed multiple thrombosis of the superficial saphenous veins (internal and external). Moreover, liver ultrasonography suggested thrombosis of the left portal vein that was further confirmed by computed tomography (CT) with contrast (Figure 1). Further laboratory examinations performed for thrombophilia (antiphospholipids antibodies, lupus anticoagulant, mutation of factor V Leiden, proteins C and S levels, mutation of prothrombin)

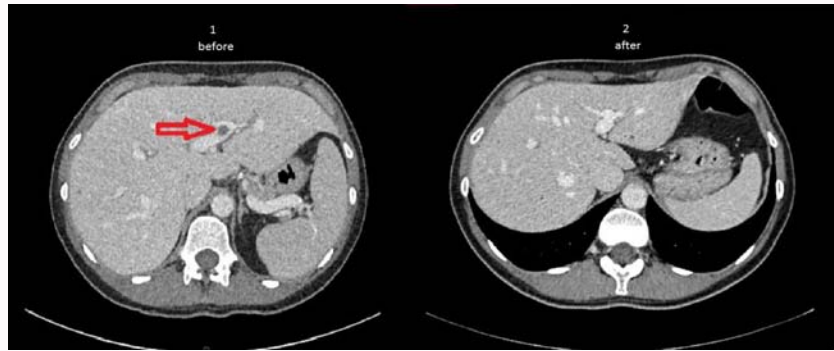


Figure 1: (1) Shows portal vein thrombosis on a CT scan of the liver (performed with infusion of contrast agent). (2) Shows the resolution of the portal vein thromboembolism six months later after anticoagulation with acoumarenol.

were all negative. Serological viral investigations were positive for acute CMV infection confirmed by an increase in serum IgG levels, 4 weeks later. The patient was treated with low molecular weight heparin subcutaneously for 2 weeks and then by oral acoumarenol with a complete clinical and biological remission. An abdominal CT performed 6 months later showed the complete disappearance of thrombosis in the portal vein (Figure 1).

Discussion

We hereby report the unusual case of a young Caucasian patient depicted by fever, lower limbs edema associated with cholestasis revealing an acute CMV infection.

There are many causes of fever of undetermined origin [1]. In most cases, they are of infectious or neoplastic origin but in a number of cases no etiology can be demonstrated. In our present case, an infectious cause was finally unshrouded. However, detection of CMV by serology assumes that the assay is performed at a certain time point from the infection such that the serum immunoglobulins M (IgM) are detectable. These develop approximately 2 weeks after the onset of clinical symptoms [2]. The patient presented a month after the onset of symptoms, which delayed the delay to detect CMV seroconversion. However, this is occasionally accompanied by false positives in the detection of serum Epstein-Barr IgM (EBV), which was the case for our patient [3]. She had performed serological tests in 2010 showing a former EBV infection with an IgG level of >750 U/mL and concomitantly a negative serological test for CMV: IgG <4 U/mL. In addition, the patient was serologically monitored for CMV at 1 month intervals showing an increase in IgG levels from 36 U/mL to 98 U/mL confirming the acute nature of the infection.

CMV infection is common with many complications, especially in immunocompromised patients. Venous thrombosis of the portal system has been described in immunocompetent patients [4]. In addition, the association of oral contraceptive use of oestrogens is involved in venous thrombosis [5]. Smoking, although a recognized cardiovascular risk factor does not appear to be involved in the occurrence of thrombosis particularly in young patients [6]. In our patient the clinical picture is probably due to a combined effect of the prothrombotic nature of contraceptive pill associated with an acute CMV infection. In a recently published paper, acute CMV infection is the culprit for venous thromboembolism whenever other predisposing factors (acquired or inherited) are present [7].

The treatment of venal portal thrombosis is based on effective anticoagulation. The duration of anticoagulation depends on the reversibility of the causes of the thrombosis and if the latter are reversible the duration of anticoagulation is typically 6 months [8]. For our patient, a treatment with acenocoumarol was initiated and the oral contraception was replaced by another means of contraception. Because there was no biological evidence of thrombophilia, long-term anticoagulation was not justified.

Conclusion

We report the case of a patient admitted for arthralgia and fever, the cause of which was a CMV infection complicated by multiple venous thrombosis, favored by the use of oral contraceptives.

References

1. Bleeker-Rovers CP, Vos FJ, de Kleijn EM, Mudde AH, Dofferhoff TS, Richter C, et al. A prospective multicenter study on fever of unknown origin: the yield of a structured diagnostic protocol. *Medicine (Baltimore)*. 2007;86(1):26-38.
2. Chou S. Newer methods for diagnosis of cytomegalovirus infection. *Rev Infect Dis*. 1990;S27-36.
3. Rhodes G, Smith RS, Rubin RE, Vaughan J, Horwitz CA. Identical IgM antibodies recognizing a glycine-alanine epitope are induced during acute infection with Epstein Barr virus and cytomegalovirus. *J Clin Lab Anal*. 1990;4(6):456-64.
4. Justo D, Finn T, Atzmony L, Guy N, Steinvil A. Thrombosis associated with acute cytomegalovirus infection: a meta-analysis. *Eur J Intern Med*. 2011;22(2):195-9.
5. Stegeman BH, de Bastos M, Rosendaal FR, van Hylckama Vlieg A, Helmerhorst FM, Stijnen T, et al. Different combined oral contraceptives and the risk of venous thrombosis: systematic review and network meta-analysis. *BMJ*. 2013;347:f5298.
6. Ageno W, Becattini C, Brighton T, Selby R, Kamphuisen PW. Cardiovascular risk factors and venous thromboembolism: a meta-analysis. *Circulation*. 2008;117(1):93-102.
7. Yildiz H, Zech F, Hainaut P. Venous thromboembolism associated with acute cytomegalovirus infection: epidemiology and predisposing conditions. *ActaClin Belg*. 2016;71(4):231-4.
8. DeLeve LD, Valla DC, Garcia-Tsao G; American Association for the Study Liver Diseases. Vascular disorders of the liver. *Hepatology*. 2009;49(5):1729-64.