



Anti-Inflammatory Mediated Wound Healing Activity of Mefenamic Acid with Honey in Wistar Rats

Sonwane V^{1*}, Somani R², Tembhurne S¹ and Kolhe S¹

¹Department of Pharmacology, Aissms College of Pharmacy, Pune 411 001, India

²Department of Pharmacology, Alkem Laboratories, Mumbai, India

Abstract

Inflammation is defined as a sequence of events that occurs in response to noxious stimuli, infection or trauma. Symptoms of inflammations are local redness, swelling, pain, heat and loss of function. The present study was performed to evaluate the anti-inflammatory and wound healing activity of Mefenamic acid in Wistar rat. The aim of present work is to study the screening of synthetic compounds for its pharmacological aspects in inflammation and wound healing activity by using various preclinical models of wound healing and inflammation. The drug was studied for their anti-inflammatory activity by using carrageenan-induced paw edema in rats and the mean increase in paw volume in paw volume were measured by plethysmometer at different time intervals after carrageenan (1% w/v) injection. The Mefenamic acid with the honey was further evaluated for wound healing activity using incision wound model. The Mefenamic acid showed significant ($p < 0.05$) reduction in the carrageenan-induced paw edema in rats and incision wound healing activity evidenced method in Wistar rats. The Mefenamic acid with honey showed a greater anti-inflammatory and wound healing effect when compared with the standard drugs, indomethacin and povidone iodine respectively. The present observation indicated significant ($p < 0.0001$) activity of the Mefenamic acid with honey in the treatment of inflammation and wound healing.

Keywords: Mefenamic acid; Inflammation; Wound healing

Introduction

Inflammation is a local response of living mammalian tissues of injury. It is a reaction in order to eliminate or limit the spread of injurious agent [1]. There are various components to an inflammatory reaction that can contribute to the associated symptoms and tissue injury. Edema, leukocyte infiltration, and granuloma formation represent such components of inflammation. Though, it is a defense mechanism. The complex events and mediators involved in the inflammatory reaction can induce or aggravate many reactions [2]. Non-steroidal anti-inflammatory drugs (NSAID) are widely used in the treatment of pain and inflammation. Mostly NSAIDs are non-selectively inhibit the two isoforms of cyclooxygenase (COX-1 and COX-2) even celcoxib and derivatives are found as selective to directly target COX-2 and thus prevent the metabolism of cellular arachidonic acid (AA) and the up regulation of prostaglandin formation, which otherwise lead to an increase of vascular permeability edema, hyperalgesia, pyrexia and inflammation [3]. A wound is an injury to a part of the body, especially one in which a damage is made in the skin. There are various types of wounds, abrasion, contusion, ulcer, and burn wound [4]. One of the most crucial phases in dermal wound healing is progressive increase in biomechanical strength of the tissue resulting from the formation and turnover of granulation tissue [5]. The mechanical property of the skin is mainly attributed to the function of the dermis in relation to the structure of collagen and elastic fiber networks [6].

Materials and Methods

Collection of drug

Mefenamic acid was collected from Alkem pharmaceuticals parel, Mumbai.

Carrageenan was procured from new neeta chemicals Pimpri, Pune.

Povidone iodine was purchased by Shri Krishna medico, near pune station, Pune -01.

Chemicals

Experimental animals: Male Wistar rats weighing 175 gm to 200 gm were used. The animals were fed with standard diet (AISSMS College of pharmacy, pune), had free access to water under

OPEN ACCESS

*Correspondence:

Vivek Sonwane, Department of Pharmacology, Aissms College of Pharmacy, Kennedy Road, Pune 411 001, India, Tel: +91-8698472651; E-mail: vickysonwane7033@gmail.com

Received Date: 06 Jun 2017

Accepted Date: 20 Jun 2017

Published Date: 26 Jun 2017

Citation:

Sonwane V, Somani R, Tembhurne S, Kolhe S. Anti-Inflammatory Mediated Wound Healing Activity of Mefenamic Acid with Honey in Wistar Rats. *Remedy Open Access*. 2017; 2: 1071.

Copyright © 2017 Sonwane V. This is an open access article distributed under the Creative Commons Attribution License, which permits unrestricted use, distribution, and reproduction in any medium, provided the original work is properly cited.

Table 1: Effect of drugs on carrageenan induced paw edema in rats.

Drugs	0hr (mean± S.D)	1hr (mean± S.D)	3hr (mean± S.D)	5hr (mean± S.D)	7hr (mean± S.D)
Control(normal saline)	0.63±0.15	1.20±0.18	1.01±0.25	0.93±0.62	0.80±0.14
Mefenamic acid with honey	0.64±0.15	1.06±0.18	0.93±0.13	0.79±0.14	0.68±0.09
Honey	0.69±0.13	1.09±0.18	0.99±0.14	0.87±0.14	0.79±0.13
Standard(indomethacin)	0.66±	1.03±0.15	0.90±0.13	0.75±0.13	0.72±0.12

Table 2: Effect of drugs on incision model in rat.

Group	Tensile strength (gm) mean± S.D
Control	294±4.96
Mefenamic acid	400±5.47
Honey	325±8.36
Povidone iodine	403±5.45

well ventilated condition of 12 h day light cycle. The animals were adapted to laboratory condition for 7 days prior to the experiments. Animals were kept in individual standard cages in standardized environmental condition with an ambient temperature of 22°C ± 2°C and a 12 h light-dark cycle. The studies were performed with the approval of Institutional Animal ethics committee (IAEC) of AISSMS College of Pharmacy, Kennedy road, Pune station, Pune (CPCSEA/IAEC/PC-04/02-2K17).

Carrageenan-induced paw edema model

Paw edema was induced by injecting 0.1 ml of 1% w/v carrageenan suspended in 1% CMC into sub-plantar tissues of the left hind paw of each rat [7]. Rats were divided into four groups; each group consisting of six animals. First group consist of Carrageenan control animal only given normal saline. Second group consist of Mefenamic acid (300 mg) drug with honey (1 ml). Animals were only given Mefenamic acid with honey by topically. Third group consists of honey (1 ml). An animal was only given honey by topically. Fourth group consist standard povidone iodine drug. An animal was only given standard povidone iodine. The paw thickness was measured before injecting the carrageenan and after 30, 60, 180, 300 and 420 minimum at various time intervals by using Plethismometer apparatus [8].

Incision wound model

The animals were divided in to a 5 groups each group consist of six animals. The animals were anaesthetized by using xylenthine (20 mg/kg i.p). Para vertebral straight incision of 2.5 cm to 3 cm length was made through the entire thickness of the skin, on either side of the vertebral column with the help of a sharp scalpel. After complete homeostasis, the wound was closed by means of interrupted sutures nylon thread at 0.5 cm apart with curved needle (no. 11) placed at equidistant points about 0.5 cm apart. First group was taken as a control this group is only treated with normal saline. Second group were taken as a standard this group is treated with standard drug povidone iodine, third group were taken as a test this group is treated with honey (1 ml), and Fourth group were treated with Mefenamic acid drug (300 mg) with honey (1 ml). All the animals got treatment as topically. Animals were treated once a day with drugs from 0 day to 9 post-wounding day. The wound breaking strength was estimated on 10 day by tensiometer apparatus. The breaking strength was expressed as minimum weight necessary to bring about gaping of area.

Results

The results are in the mean of 5 animals in each group ± SD. The graph indicates significant (P<0.05**) shows significant effect of

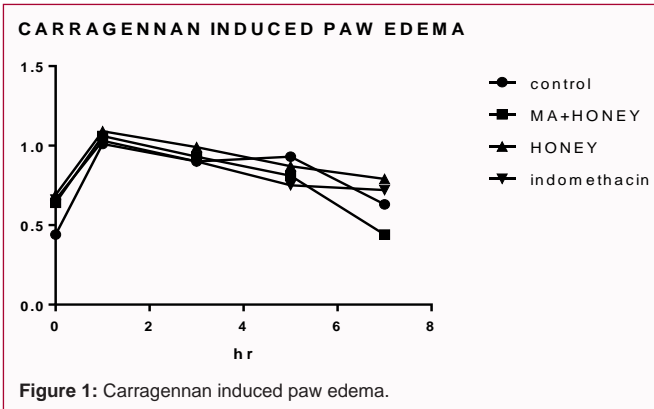


Figure 1: Carrageenan induced paw edema.

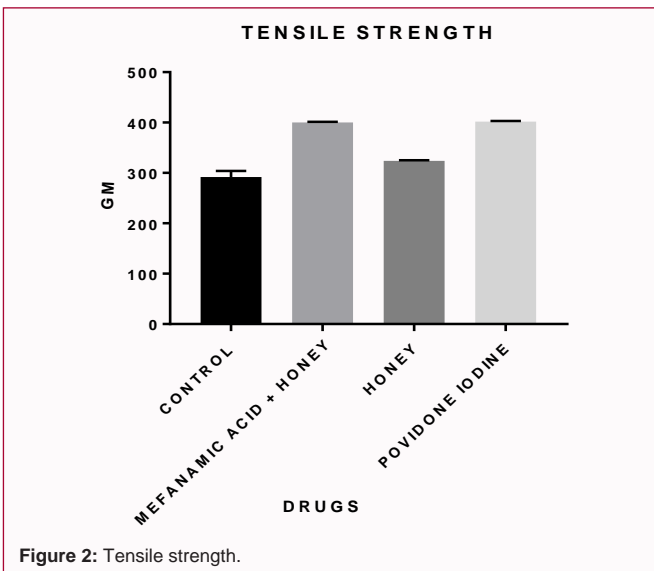


Figure 2: Tensile strength.

drugs as compare to control reduction in paw edema volume after 7 h of carrageenan injection (ANOVA followed by one way ANOVA) (Table 1 and Figure 1).

The results are in the mean of 5 animals in each group ± SD. The graph indicates significant (P<0.001***) *** shows very significant effect of all drugs in incision animal model as compare to control (ANOVA followed by one way ANOVA) (Table 2 and Figure 2).

Discussion

The present study demonstrates the anti-inflammatory action of Honey and Mefenamic acid in rats. The activity of honey and Mefenamic acid (P<0.05, ANOVA) was comparable to indomethacin (NSAID), when tested against carrageenan induced paw edema on rat. On rats both indomethacin as a standard and Mefenamic acid as a test drugs shows a significant decline in paw edema on paw edema [9]. The administration of current anti-inflammatory drugs is often associated with severe side effects. For the past few decades, the world population up to 75% to 80% relies on herbal medicines,

for primary health care especially in developing countries, because of their better acceptability with human body and lesser side effects [10-12]. Hence alternative therapeutic modules are necessitated [13]. Few investigations have been initiated around the globe into researching, screening and analyzing the local plants with anti-inflammatory values. Carrageenan-induced rat paw edema model is a suitable test for evaluating anti-inflammatory drugs, which has frequently been used to assess the anti-edematous effect of the drug. Carrageenan is a strong chemical used for the release of inflammatory and pro-inflammatory mediators (prostaglandins, leukotrienes, histamine, bradykinin, TNF-alpha, etc.) [14].

One of the most important factors in the healing of wounds is the stimulation of wound strength [15]. Wound strength is determined by the amount and quality of newly synthesized and deposited collagen, as well as degradation of preformed collagen [16]. Tensile strength, which demonstrates the force per unit of cross sectional area needed to break the wound, is an important measure since it reflects the sub dermal organization of the collagen fibres in the newly deposited collagen [15]. Tensile strength indicates how much the repaired tissue resists breaking under tension and may indicate in part the quality of the repaired tissue [17]. Collagen is one of the major components that is mainly responsible for the mechanical properties of the skin [18]. The net amount of wound collagen deposition depends on collagen turnover and is a reflection of collagen synthesis minus collagen breakdown [16]. The changes in the diameter of collagen fibrils have also been related to mechanical strength of the skin. Apparently thick collagen fibrils can resist greater tensile strength as opposed to thin ones [19]. Once the skin is injured, the normal collagen will be replaced by scar collagen and the connective tissue will not regain the original highly organized structure of collagen. Thus, the healing skin is weaker and results in lower tensile strength as opposed to the normal skin [20]. In this study, the initial phase of wound healing was characterized by low tensile strength, which resulted from the severing of collagen bundles and fibrils at the wound site. Heat denaturation, such as in thermal burn, destroys the helical structure of the collagen molecule and if the temperature is sufficiently high, cleaves the Schiff-base bond thus solubilizing a fraction of intact collagen as a high molecular weight gelatine [21]. Newly formed collagen does not possess any substantial mechanical strength until cross-links of the Schiff-base type have been formed between collagen molecules and this process is catalysed by lysyl-oxidase [19]. Although the mechanical strength of soft connective tissues is mediated by the collagen, there are no substantial amounts of collagen present in a wound until after 2 to 3 days of healing [22]. This is due to the fibroblast proliferation and collagen synthesis, which usually begins 2 to 3 days post wounding [15]. A slow increase in wound tensile strength corresponds to the increase in fibroblasts, which begin to produce immature collagen during the proliferative phase of wound healing [15]. Fibroblasts play an important role in producing the collagen necessary to restore the tensile strength of wounded skin [23]. Have proved that honey enhanced collagen synthesis, particularly by stimulating the activity of fibroblasts due to the sugars present in honeys. Al-Jady et al. [24] have demonstrated that honey treatment significantly increased cell proliferation in the newly formed granulation tissues.

Conclusion

This experiment showed that the carrageenan successfully induced edema in the paw. Mefenamic acid with honey reduced the

paw volume indicated anti-inflammatory property as well as wound healing property. The findings of the present experimental study appear to be clinically relevant since such drugs are likely to be used chronically in inflammation and wound healing who are prone for injury [25], though Mefenamic acid is commonly used as an anti-inflammatory drug.

References

1. Mahat MA, Patil BM. Evaluation of anti-inflammatory activity of methanol extract of *Phyllanthus amarus* in experimental animal model. *Int J Inflamm*. 2007;69:33-6.
2. Sosa S, Balick MJ, Arvigo R, Esposito RG, Pizzi C, Altinier G, et al. Screening of the topical anti-inflammatory activity of some central American plants. *J Ethnopharmacol*. 2002;81(2):211-2005.
3. Charlier C, Michaux C. Dual inhibition of cyclo-oxygenase-2 (COX-2) and 5-lipoxygenase (5-LOX) as a new strategy to provide safer non-steroidal anti-inflammatory drugs. *Eur j med chem*. 2003;38(7-8):645-59.
4. Leaper DJ, Harding KG. *Wound: Biology and Management*. Oxford University Press Hongkong. 1998.
5. Paul RG, Tarlton JF, Purslow PP, Sims TJ, Watkins P, Marshall F, et al. Biomechanical and biochemical study of a standardized wound healing model. *Int J Biochem Cell Biol*. 1997;29(1):211-20.
6. Daly CH. Biomechanical properties of dermis. *J Invest Dermatol*. 1982;79:17-20.
7. Winter CA, Risley EA, Nuss GV. Carrageenan induced edema in hind paw of the rat an assay for anti-inflammatory drugs. *Proc Soc Exp Biol Med*. 1962;111:544-7.
8. Lanhers MC, Fleurentin J, Mortier F, Vinche A, Younos C. Anti-inflammatory and analgesic effects of an aqueous extract of *Harpagophytum procumbens*. *Planta Med*. 1992;58(2):117-23.
9. Potawale SE, Yeole Du, Deshmukh rani, Patl VG, Khopde AN, Purohit AP. Design, Development and evaluation of herbal wound healing formulation. *Adv Pharmacol Toxicol*. 2007;8(3):99-103.
10. Satyanand V, Reddy CB, Rama Mohan P, Kumar MR, Narayanaswamy DL, Seelam A, et al. Effects of Garlic extract (*Allium sativum*) in combination with Amlodipine in mild to moderate essential hypertensive patients: An Open randomized parallel group study. *J Pharm Res Dev*. 2013;2(4):181-8.
11. Satyanand V, Krishnan TV, Ramalingam K, Rao PS, Priyadarshini S. Blockade of voltage dependent calcium channels lowers the high blood pressure through ginger. *Int J Analyt Pharm Biomed Sci*. 2013;2(1):64-6.
12. Satyanand V, Venkat Krishnan, Madhavi D, Revathi, Indira S, Shaik AB, et al. The effect of peppermint juice for indigestion among old age people- A preliminary study. *J Pharm Res Dev*. 2013;2(7):238-43.
13. Gurib-Fakim A. Medicinal plants: traditions of yesterday and drugs of tomorrow. *Mol Aspects Med*. 2006;27(1):1-93.
14. Wills AL. Release of histamine, kinin and prostaglandins during carrageenan induced inflammation of the rats," in prostaglandins, peptides and amines. Montagazza P Horton EW, editors. Academic Press, London, UK. 1969:31-48.
15. Jimenez PA, Rampy MA. Keratinocytes Growth Factor-2 accelerates wound healing in incisional wounds. *J Surg Res*. 1999;81:238-42.
16. Witte MB, Thornton FJ, Kiyama T, Efron DT, Schulz GS, Moldawer LL, et al. Metalloproteinase inhibitors and wound healing: A novel enhancer of wound strength. *Surgery*. 1998;124:464-70.
17. Rashed AN, Afifi FU, Disi AM. Simple evaluation of the wound healing activity of a crude extract of *Portulaca oleracea L.* (growing in Jordan) in *Mus musculus JVI-1*. *J Ethnopharmacol*. 2003;88(2-3):131-6.
18. Oxlund H, Andreassen TT. The roles of hyaluronic acid, collagen

- and elastin in the mechanical properties of connective tissues. *J Anat*. 1980;131(Pt 4):611-20.
19. Jorgensen PH, Andreassen TT, Jorgensen KD. Growth hormone influences collagen deposition and mechanical strength of intact rat skin. A dose-response study. *Acta Endocrinol (Copenh)*. 1989;120:767-72.
20. Diegelmann RF. Collagen Metabolism. *Wounds*. 2001;13(5):177-82.
21. Quirinia A, Viidik A. The influence of age on the healing of normal and ischemic incisional skin wounds. *Mech Ageing Dev*. 1991;58(2-3):221-32.
22. Lu WW, Ip WY, Jing WM, Holmes AD, Chow SP. Biomechanical properties of thin skin flap after basic fibroblast growth factor (bFGF) administration. *Br J Plast Surg*. 2000;53(3):225-9.
23. Jørgensen PH, Andreassen TT. Influence of biosynthetic human growth hormone on biomechanical properties of rat skin incisional wounds. *Acta Chir Scand*. 1988;154(11-12):623-6.
24. Al-jady AM, Kamaruddin MY, Jamal AM, Mohd-Yassim MY. Biochemical study on the efficacy of Malaysian Honey on inflicted wounds: an animal model. *Medical J Islamic Acad Sci*. 2000;13(3):125-32.
25. Ashley NT, Zachary MW, Nelson RJ. Inflammation: Mechanisms, costs, and natural variation. *Annu Rev Ecol Evol Syst*. 2012;43:385-406.