



Osteonecrosis of the Femoral Head in an HIV-Infected Patient on a Protease Inhibitor-Sparing Antiretroviral Combination

Chiquini MC¹, Eyer-Silva WA^{1*}, Albuquerque CF², Ramos MRF¹, da Silva GAR¹, Oliveira RPB¹, Pinto JFC¹ and Ferry FRA¹

¹Department of Biological and Health Sciences, Federal University of the State of Rio de Janeiro, Rio de Janeiro, Brazil

²Department of Orthopedics, Central Army Hospital, Rio de Janeiro, Brazil

Abstract

Physicians who care for HIV-infected patients are being challenged to deal with osteonecrosis as an emerging complication. The role of protease inhibitors (PI) as a risk factor remains to be better defined. Osteonecrosis of the femoral head is a debilitating disease that usually leads to destruction of the hip joint and requires total hip arthroplasty as a definitive treatment. We present the case of a 34 year-old female patient who developed osteonecrosis of the femoral head 4 years after initiation of a successful PI-sparing antiretroviral combination. Health care providers should have a low threshold for osteonecrosis investigation in HIV-infected subjects.

Keywords: Antiretroviral therapy; HIV Infection; Osteonecrosis

OPEN ACCESS

*Correspondence:

Walter de Araujo Eyer Silva,
Department of Biological and Health
Sciences, 10a infirmary, Gaffrée and
Guinle University Hospital, Federal
University of the State of Rio de
Janeiro, Mariz e Barros Street, 775,
Tijuca, CEP 20270-004, Rio de Janeiro
(RJ), Brazil, Tel: 55 21 999537051;
E-mail: walter.eyer@ig.com.br

Received Date: 04 Mar 2017

Accepted Date: 02 Jun 2017

Published Date: 12 Jun 2017

Citation:

Chiquini MC, Eyer-Silva WA,
Albuquerque CF, Ramos MRF, da
Silva GAR, Oliveira RPB, et al.
Osteonecrosis of the Femoral Head
in an HIV-Infected Patient on a
Protease Inhibitor-Sparing Antiretroviral
Combination. *Remed Open Access*.
2017; 2: 1064.

Copyright © 2017 Eyer-Silva WA. This
is an open access article distributed
under the Creative Commons Attribution
License, which permits unrestricted
use, distribution, and reproduction in
any medium, provided the original work
is properly cited.

Introduction

Physicians who care for human immunodeficiency virus (HIV)-infected patients are being challenged to deal with osteonecrosis as an emerging complication. Osteonecrosis, or avascular necrosis, is the death of bone tissue, including the bone marrow, usually as a result of impaired arterial blood supply [1,2]. The most vulnerable site is the femoral head. It is a debilitating disease that usually leads to destruction of the hip joint and requires total hip replacement as definitive treatment. A myriad of systemic factors are associated with osteonecrosis, mainly hypercholesterolemia, glucocorticoid administration, and trauma. Other important predisposing factors include excessive alcohol intake, connective tissue disorders, intravenous drug use, deep sea diving or other hyperbaric conditions, coagulopathy, and hemoglobinopathies [3-6].

It has been estimated that the incidence of osteonecrosis among HIV-infected patients is 45 times greater than would be expected in the general population [1,2]. Reports of HIV-associated osteonecrosis are available since the early 1990's [1,7-9]. Since some patients had no known risk factors, it has been suggested that HIV infection itself may stand as a novel predisposing condition. Some authors suggested that antiretroviral therapy (ART) that include a protease inhibitor (PI) play a role in the development of osteonecrosis through mechanisms such as its tendency to cause hyperlipemia [10-14]. Others found no difference in overall PI use among cases and controls [15]. It has also been suggested that osteonecrosis could be the result of immunologic recovery after initiation of ART [16], which would place it as a novel feature of the immune reconstitution inflammatory syndrome. However, some HIV-infected patients develop osteonecrosis while on a non PI-including combination [17] or even before initiation of ART [7]. We report on the case of a patient who developed osteonecrosis 4 years after initiation of PI-sparing ART.

Case Presentation

A 34 year-old female patient with a recent diagnosis of HIV infection started follow up at our outpatient unit in June 2008. She had oral candidiasis and had lost weight in the previous months. Pneumocystis pneumonia was treated with trimethoprim-sulfamethoxazole and a short course of corticosteroids. Her CD⁴ cell count was 341 cells/mm³. ART composed of three reverse transcriptase inhibitors (zidovudine, lamivudine and nevirapine) was started. Plasma viral load could not be obtained prior to treatment initiation. Since then, all viral load measurements yielded undetectable levels.

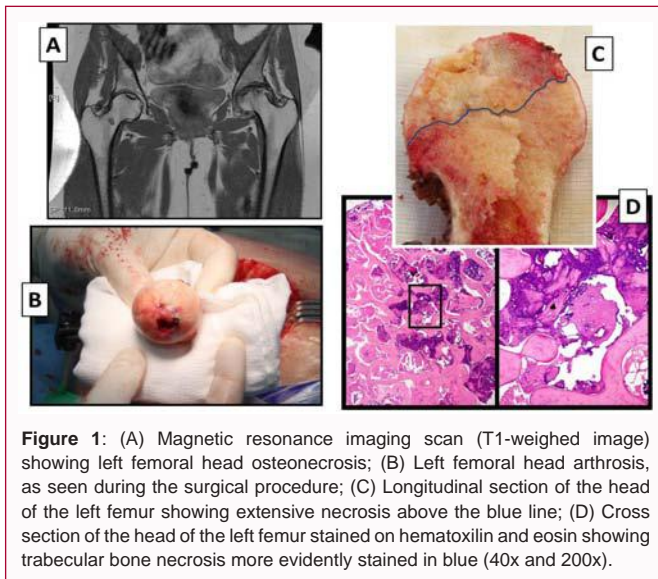


Figure 1: (A) Magnetic resonance imaging scan (T1-weighted image) showing left femoral head osteonecrosis; (B) Left femoral head arthrosis, as seen during the surgical procedure; (C) Longitudinal section of the head of the left femur showing extensive necrosis above the blue line; (D) Cross section of the head of the left femur stained on hematoxylin and eosin showing trabecular bone necrosis more evidently stained in blue (40x and 200x).

Four years later she developed new-onset left hip pain that worsened with walking. An antalgic gait was evident. The patient had no history of smoking, use of alcohol or illicit drugs, hematological or coagulation abnormalities. She informed that her only medications were the antiretroviral combination composed of zidovudine, lamivudine and nevirapine. Active and passive mobilization of the left coxo-femoral articulation, as well as internal and external hip rotation, were limited by pain. At this point the CD⁴ cell count was 775 cells/mm³. Physical therapy and non-steroidal anti-inflammatory drugs were started. Pain progressively worsened during the ensuing 2 years. Laboratory evaluations showed an LDL cholesterol in the upper normal limit (131 mg/dl) and was otherwise unremarkable. Plain radiographs and computed tomography scans revealed changes consistent with osteonecrosis of the left femoral head: loss of sphericity of both femoral heads, more advanced on the left, subchondral collapse, left femoral head collapse, subchondral cyst formation, and sclerosis. Magnetic resonance imaging (MRI) showed that the antero-medial aspect of the left femoral head had an osteochondral lesion of low signal intensity on T1-weighted images (Figure 1A), surrounded by a rim of hyperintensity signal on short tau inversion recovery (STIR) images, corresponding to extensive bone infarct. The lesion measured 3.5 cm × 1.8 cm × 2 cm.

Total hip arthroplasty was performed (Figure 1B) in July 2015. She experienced an uneventful recovery. Pathological examination (Figure 1C and 1D) revealed trabecular bone necrosis, overlying articular cartilage degeneration, marrow fibrosis and fat infiltration. No evidence of osteomyelitis was found.

Discussion

There is no specific features on history or physical examination to indicate a diagnosis of osteonecrosis. Pain and disability may result from microfracture, damage to articular surfaces, and swelling of the bone marrow [1]. In early cases, a high index of suspicion is necessary. MRI is considered the imaging method with the highest sensitivity and specificity, whereas computed tomography is the most sensitive for detecting subchondral fractures [18]. Given their low cost and simplicity, plain radiographs are the most appropriate initial test in the management of hip pain. In advanced disease, a subchondral fracture, also known as the “crescent sign” is suggestive of osteonecrosis [18].

HIV-associated osteonecrosis is probably a multifactorial disorder. HIV infection and ART are likely contributing factors by themselves. One study found a marked increase in the annual incidence of osteonecrosis in HIV-infected patients between 1990 and 2000 [19]. The frequency of osteonecrosis increased from 1.6 per 1000 AIDS patients during 1993–1996 to 14 per 1000 patients in 1997–2000, which seems to have a temporal relationship with the availability of PI [19]. In fact, a prospective MRI-based study found an unexpectedly high incidence of osteonecrosis of the femoral head in 15 (4.4%) out of 339 asymptomatic HIV-infected patients [20].

A major issue is the possibility of drug interactions with the PI ritonavir, commonly used as a booster to other PIs. It is known that ritonavir significantly increases the systemic exposure to corticosteroids [21,22]. Some case reports have been published on the emergence of osteonecrosis in PI-treated HIV-infected patients who have been prescribed inhaled corticosteroids [23,24]. Our patient had no other traditional risk factors for the development of osteonecrosis, other than an LDL cholesterol in the upper limit of normality. She was a non smoker and was not on any other drug besides her PI-sparing ART. It seems unlikely that the short course of glucocorticoids administered 4 years earlier has played a role in the development of osteonecrosis.

Health care providers should be aware of this emerging complication of HIV infection and should offer HIV testing to all patients with a diagnosis of osteonecrosis. A low threshold to osteonecrosis investigation in HIV-infected patients should be exercised, since its incidence is probably underestimated. The role of ART as a predisposing factor to osteonecrosis requires additional investigations. Even though many authors have suggested an association with the use of PI, it should be stressed that osteonecrosis may occur under a PI-sparing regimen, as has occurred in the present case, and even prior to initiation of ART, as previously reported in the literature.

References

1. Goorney BP, Lacey H, Thurairajasingam S, Brown JD. Avascular necrosis of the hip in a man with HIV infection. *Genitourin Med.* 1990;66:451-2.
2. O'Gradaigh D, Crisp A. Osteonecrosis, osteochondrosis, and osteochondritis dissecans. In: Warrel DA, Cox TM, Firth JD, editors. *Oxford Text book of Medicine.* 5th ed. Oxford: Oxford University Press. 2010.
3. Moskal JT, Topping RE, Franklin LL. Hypercholesterolemia: an association with osteonecrosis of the femoral head. *Am J Orthop (Belle Mead NJ).* 1997;26:609-12.
4. Weinstein RS. Glucocorticoid-induced osteonecrosis. *Endocrine.* 2012;41:183-90.
5. Bachiller FG, Caballer AP, Portal LF. Avascular necrosis of the femoral head after femoral neck fracture. *Clin Orthop Relat Res.* 2002;399:87-109.
6. Eholié SP, Ouiminga M, Ehui E, Nzunetu G, Ouattara SI, Konan AV, et al. Avascular osteonecrosis of the femoral head in three West African HIV-infected adults with heterozygous sickle cell disease. *Antivir Ther.* 2009;14:1011-4.
7. Gerster JC, Camus JP, Chave JP, Koeger AC, Rappoport G. Multiple site avascular necrosis in HIV infected patients. *J Rheumatol.* 1991;18:300-2.
8. Chevalier X, Larget-Piet B, Hernigou P, Gherardi R. Avascular necrosis of the femoral head in HIV-infected patients. *J Bone Joint Surg Br.* 1993;75:160.
9. Matos MA, Alencar RW, Matos SS. Avascular necrosis of the femoral head

- in HIV infected patients. *Braz J Infect Dis.* 2007;11:31-4.
10. Scribner AN, Troia-Cancio PV, Cox BA, Marcantonio D, Hamid F, Keiser P, et al. Osteonecrosis in HIV: a case-control study. *J Acquir Immune Defic Syndr.* 2000;25:19-25.
 11. Meyer D, Behrens G, Schmidt RE, Stoll M. Osteonecrosis of the femoral head in patients receiving HIV protease inhibitors. *AIDS.* 1999;13:1147-8.
 12. Aguiar De Aragão P, Lemos RB, Aquino MZ, Souza Marques HH. Hyperlipidaemia a risk factor for femoral head osteonecrosis (Legg-Calv-Perthes-like disease) in children with AIDS: case report. *Braz J Infect Dis.* 2002;6:142-5.
 13. Bongiovanni M, Chiesa E, Riva A, d'Arminio Monforte A, Bini T. Avascular necrosis of the femoral head in a HIV-1 infected patient receiving lopinavir/ritonavir. *Int J Antimicrob Agents.* 2003;22:630-1.
 14. Porsch M, König DP, Popken F. Possible complication of HIV therapy. Protease inhibitor-induced femur head necrosis. *MMW Fortschr Med.* 2001;143:90-1.
 15. Monier P, McKown K, Bronze MS. Osteonecrosis complicating highly active antiretroviral therapy in patients infected with human immunodeficiency virus. *Clin Infect Dis.* 2000;31:1488-92.
 16. Permpalung N, Ungprasert P, Summachiwakij S, Leeaphorn N, Knight EL. Protease inhibitors and avascular necrosis: a systematic review and meta-analysis. *Int J Antimicrob Agents.* 2014;44:93-5.
 17. Choi HR, Steinberg ME, Y Cheng E. Osteonecrosis of the femoral head: diagnosis and classification systems. *Curr Rev Musculoskelet Med.* 2015;8:210-20.
 18. Brown P, Crane L. Avascular necrosis of bone in patients with human immunodeficiency virus infection: report of 6 cases and review of the literature. *Clin Infect Dis.* 2001;32:1221-6.
 19. Gutierrez F, Padilla S, Ortega E, García JA, Flores J, Galera C, et al. Avascular necrosis of the bone in HIV-infected patients: incidence and associated factors. *AIDS.* 2002;16:481-3.
 20. Miller KD, Masur H, Jones EC, Joe GO, Rick ME, Kelly GG, et al. High prevalence of osteonecrosis of the femoral head in HIV-infected adults. *Ann Intern Med.* 2002;137:17-25.
 21. Penzak SR, Formentini E, Alfaro RM, Long M, Natarajan V, Kovacs J. Prednisolone pharmacokinetics in the presence and absence of ritonavir after oral prednisone administration to healthy volunteers. *J Acquir Immune Defic Syndr.* 2005;40:573-80.
 22. Foisy MM, Yakiwchuk EM, Chiu I, Singh AE. Adrenal suppression and Cushing's syndrome secondary to an interaction between ritonavir and fluticasone: a review of the literature. *HIV Med.* 2008;9:389-96.
 23. Kaviani N, Bukberg P, Manassis A, Yen V, Young I. Iatrogenic osteoporosis, bilateral HIP osteonecrosis, and secondary adrenal suppression in an HIV-infected man receiving inhaled corticosteroids and ritonavir-boosted highly active antiretroviral therapy. *Endocr Pract.* 2011;17:74-8.
 24. Pollett S, Graves B, Richards B, MacLeod C. Avascular necrosis in a HIV patient receiving ritonavir and inhaled fluticasone. *Int J STD AIDS.* 2014;25:458-60.