



# Influence of Control Data on Diffusion Tensor Imaging in Cervical Spondylotic Myelopathy

Kevin Yuqi Wang<sup>1\*</sup>, Oluwatoyin Idowu<sup>2</sup> and Izlem Izbudak<sup>2</sup>

<sup>1</sup>Department of Radiology, Baylor College of Medicine, Houston, Texas, USA

<sup>2</sup>Department of Radiology and Radiological Science, Johns Hopkins University School of Medicine, Baltimore, Maryland, USA

## Abstract

**Purpose:** The aim of this study is to use receiver operating characteristic (ROC) analysis to evaluate the influence of the varying intervertebral disc levels chosen as control groups on the comparative analysis of diffusion tensor imaging (DTI) in patients with cervical spondylotic myelopathy (CSM).

**Methods:** Magnetic resonance imaging (MRI) of the cervical spinal cord was performed in 8 CSM patients and in 5 healthy volunteers on a 3-T MRI scanner. Fractional anisotropy (FA) and mean diffusivity (MD) were calculated on axial imaging and sagittal imaging at the level of maximal stenosis in patients, and varying disc levels from C2-C3 through C7-T1 in controls. ROC analysis was used to assess the discriminatory ability of FA and MD in distinguishing controls and CSM patients when utilizing different disc levels as control groups. Areas under the curve (AUC) across the controls groups were considered statistically significant if 95% binomial confidence intervals did not overlap.

**Results:** The highest AUC in MD was 0.80 when utilizing level C4-C7 in healthy volunteers as a control. The highest AUC in FA was 0.80 when level C2-C5 in healthy volunteers was chosen as a control. No non-overlapping 95% confidence intervals of the AUC were noted among the differing control groups for MD or FA.

**Conclusion:** Evaluating the variable components in DTI acquisition and analysis in CSM, such as the inter-study variation in disc levels as controls groups, may further optimize approaches to evaluate CSM with DTI.

**Keywords:** Diffusion tensor imaging; Spinal cord; Cervical spondylotic myelopathy; Magnetic resonance imaging

## Introduction

Cervical spondylosis is a common degenerative disorder often comprising osteophytosis, disc herniation, and ligamentum flavum hypertrophy, which leads to narrowing of the cervical canal, and in certain instances cervical spondylotic myelopathy (CSM) [1]. Conventional magnetic resonance imaging (MRI) is commonly utilized in the clinical setting for the evaluation of CSM. However, discrepancies between MRI findings and neurological function as well as surgical outcome limit its utility in evaluation and management [2]. Particularly during the early clinical manifestation of CSM, conventional MRI may not often reveal an intramedullary signal to suggest an abnormality.

Diffusion tensor imaging (DTI), an MRI technique sensitive to the directionality of the diffusion of water molecules as means to evaluate microstructural changes within tissues, may be a valuable adjunct to conventional MRI. Preliminary studies investigating the utility of DTI in the spinal cord have demonstrated that DTI metrics in patients with CSM differ to those of healthy volunteers [3-7], correlate with certain clinical scores [6,8], and predict postoperative outcomes [6,9,10].

However, the widespread use of DTI in evaluating CSM is limited by the lack of standardized methods for data acquisition and post-processing analysis [11]. For example, studies vary in b-values, gradient directions, and field strengths, which may ultimately affect calculation of DTI metrics. Moreover, when comparing DTI metrics of patients with CSM to those of controls, studies differ in the segments chosen for control groups. For example, disc levels utilized as control groups have included C2-C3 [5], C2-C5 [12], C2-C6 [13], C2-C7 [14], C5-C6 [15], C4-C7 [8], and C2-T1 [16] in healthy volunteers, and nonstenotic levels (e.g. C2-C3) in CSM patients [17,18]. It is uncertain to what extent such variation affects interpretation of DTI metrics, and a more thorough

## OPEN ACCESS

### \*Correspondence:

Kevin Yuqi Wang, Department of Radiology, Baylor College of Medicine, One Baylor Plaza Houston, TX 77030, USA, Tel: 713-798-6362; Fax: 713-798-8359;

E-mail: [yuqiw@bcm.edu](mailto:yuqiw@bcm.edu)

Received Date: 27 Feb 2017

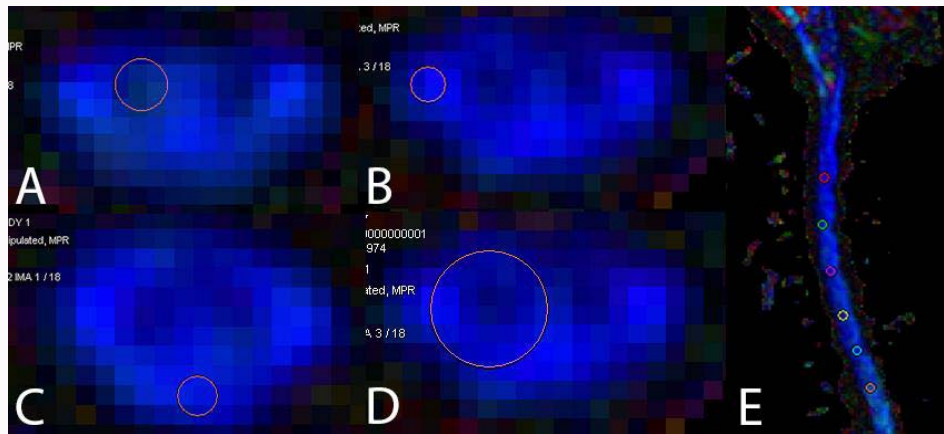
Accepted Date: 13 Mar 2017

Published Date: 28 Mar 2017

### Citation:

Wang KY, Idowu O, Izbudak I. Influence of Control Data on Diffusion Tensor Imaging in Cervical Spondylotic Myelopathy. *Remed Open Access*. 2017; 2: 1047.

**Copyright** © 2017 Kevin Yuqi Wang. This is an open access article distributed under the Creative Commons Attribution License, which permits unrestricted use, distribution, and reproduction in any medium, provided the original work is properly cited.



**Figure 1:** Color-coded FA map showing region of interest placements approximating the anterior grey matter(A), lateral white matter (B) posterior white matter (C), hemi-axial cord (D), and anterior-posterior diameter of the sagittal cord (E).

characterization of the influence of differing segments in controls may further our understanding in the optimal utilization of DTI in CSM. In this study, we aim to use receiver operating characteristic (ROC) curves to characterize the influence of the intervertebral disc levels chosen as controls on DTI metrics' ability to discriminate between patients with CSM and controls.

## Materials and Methods

### Study subjects

Eight patients with the diagnosis of CSM were included in this study, and were diagnosed based on a combination of clinical and imaging features (8 males, mean age: 62.4 year's old, range: 50-84 years old). Five healthy volunteers (3 males, 2 females, mean age: 48 years of age, range: 39-53 years of age) without neurological symptoms or known spinal disease were included and designated as controls. Approval from the Institutional Review Board was obtained for the current study, and the study complies with the Health Insurance Portability and Accountability Act. Informed consent was provided to all subjects prior to the start of the study.

### MRI protocol

MRI exams were obtained with a 3-T research MRI scanner (Magnetom Tim Trio, Siemens Healthcare, Germany) using a standard 4-element neck matrix coil and the standard 32-element spine matrix coil. Conventional sequences of the spine were obtained and included sagittal and axial T1- and T2-weighted turbo spin echo imaging and sagittal short inversion time inversion recovery sequences. A multi-slice, multi-shot, interleaved, spin echo, echo planar imaging pulse sequence with parallel imaging and an acceleration factor of two was used to obtain sagittal DTI of the cervical spinal cord. Scan parameters of the acquired DTI images are as follows: TR=3200 ms; TE=73 ms; field-of-view of 200 mm; slice thickness of 2.5 mm; and imaging matrix of 176x176 with an in-plane resolution of 1.2 mm x 1.2 mm. To minimize eddy current effects and susceptibility and motion artifacts from adjacent tissue interfaces along the phase encoding direction, balanced pairs of gradients and saturation bands anterior to the cervical spine were used, respectively. A total of 10 directions were sampled with b-values 0 mm<sup>2</sup>/s and 750 mm<sup>2</sup>/s without respiratory and cardiac gating. The same multi-shot technique was used for axial DTI of the cervical spinal cord with the following scan parameters: TR=2500 ms; TE=90 ms; field-of-view of 200 mm; slice thickness of 5.0 mm; imaging matrix of 120x236.

### Image post-processing

Post-processing of raw DTI data was performed offline on a workstation using the Siemens Neuro 3D post-processing software. FA and MD measurements were calculated on a voxel-by-voxel basis, thereby generating grey-scale maps of these metrics from which FA and MD values can be obtained. For each CSM patient, MD and FA values were measured at the intervertebral disc level of maximal cervical canal stenosis. Regions of interests (ROIs) were placed on the slight-anterior, posterior, and lateral regions of the axial spinal cord, which approximate and correspond to the locations of the anterior grey matter, dorsal column, and corticospinal tract, respectively (Figure 1). In addition, MD and FA values were also measured with larger ROIs that approximated the near-entire anteroposterior region of the hemi-axial cord and sagittal cord (Figure 1). For each control, similar ROIs were placed at varying intervertebral disc levels as specified in prior studies [5,8,12-18]. Attention in maintaining distance between ROIs and the edge of the spinal cord was made to mitigate potential partial volume effect by adjacent cerebrospinal fluid.

### Statistical analysis

ROC analysis was used to assess discriminatory ability of FA and MD when utilizing different disc levels as control groups. Statistical analyses were performed using STATA v13.0 (STATA Corp, College Station, Texas, 2013), and the area under the curves (AUCs) and 95% binomial confidence intervals (CIs) were calculated.

## Results

Table 1 depicts the AUC for FA and MD according to control groups based on varying intervertebral disc levels. The highest AUC in MD was 0.80 when analyzing either the hemi-axial cord region or anterior grey matter region and utilizing level C4-C7 in healthy volunteers as a control. The highest AUC in FA was 0.80 when analyzing the anterior grey matter region of the cord and level C2-C5 in healthy volunteers was chosen as a control. No non-overlapping 95% confidence intervals of the AUC were noted among the differing intervertebral disc level control groups for MD or FA, suggesting no statistically significant differences in discriminatory power among the various intervertebral disc levels chosen for controls.

## Discussion

There is significant inter-study variability in the disc segments

**Table 1:** Receiver operating curve analysis of FA and MD according to different control groups based on varying intervertebral disc levels.

| Control Disc Level | Sagittal (AUC)    |                   | Axial (AUC)       |                   |
|--------------------|-------------------|-------------------|-------------------|-------------------|
|                    | FA (95% CI)       | MD (95% CI)       | FA (95% CI)       | MD (95% CI)       |
| C2-C3              | 0.53 (0.25, 0.81) | 0.40 (0.14, 0.68) | 0.63 (0.32, 0.86) | 0.63 (0.32, 0.86) |
| ^C2-C3             | 0.43 (0.19, 0.75) | 0.55 (0.25, 0.81) | 0.45 (0.19, 0.75) | 0.40 (0.14, 0.68) |
| C5-C6              | 0.65 (0.32, 0.86) | 0.60 (0.18, 0.86) | 0.40 (0.14, 0.68) | 0.78 (0.46, 0.95) |
| C4-C7              | 0.65 (0.32, 0.86) | 0.68 (0.39, 0.91) | 0.38 (0.14, 0.68) | 0.80 (0.46, 0.95) |
| C2-C5              | 0.48 (0.19, 0.75) | 0.58 (0.25, 0.81) | 0.63 (0.32, 0.86) | 0.68 (0.39, 0.91) |
| C2-C6              | 0.48 (0.19, 0.75) | 0.63 (0.32, 0.86) | 0.50 (0.25, 0.81) | 0.70 (0.39, 0.91) |
| C2-C7              | 0.53 (0.25, 0.81) | 0.63 (0.32, 0.86) | 0.43 (0.19, 0.75) | 0.73 (0.39, 0.91) |
| Control Disc Level | LWM (AUC)         |                   | AGM (AUC)         |                   |
|                    | FA (95% CI)       | MD (95% CI)       | FA (95% CI)       | MD (95% CI)       |
| C2-C3              | 0.45 (0.19, 0.75) | 0.38 (0.14, 0.68) | 0.65 (0.32, 0.86) | 0.53 (0.25, 0.81) |
| ^C2-C3             | 0.43 (0.19, 0.75) | 0.53 (0.25, 0.81) | 0.45 (0.19, 0.75) | 0.35 (0.14, 0.68) |
| C5-C6              | 0.35 (0.14, 0.68) | 0.48 (0.19, 0.75) | 0.55 (0.25, 0.81) | 0.70 (0.39, 0.91) |
| C4-C7              | 0.38 (0.14, 0.68) | 0.43 (0.19, 0.75) | 0.60 (0.18, 0.86) | 0.80 (0.46, 0.95) |
| C2-C5              | 0.43 (0.19, 0.75) | 0.40 (0.14, 0.68) | 0.80 (0.46, 0.95) | 0.65 (0.32, 0.86) |
| C2-C6              | 0.43 (0.19, 0.75) | 0.38 (0.14, 0.68) | 0.75 (0.46, 0.95) | 0.65 (0.32, 0.86) |
| C2-C7              | 0.40 (0.14, 0.68) | 0.38 (0.14, 0.68) | 0.73 (0.39, 0.91) | 0.73 (0.39, 0.91) |
| Control Disc Level | PWM (AUC)         |                   |                   |                   |
|                    | FA (95% CI)       | MD (95% CI)       |                   |                   |
| C2-C3              | 0.53 (0.25, 0.81) | 0.70 (0.39, 0.91) |                   |                   |
| ^C2-C3             | 0.58 (0.25, 0.81) | 0.48 (0.19, 0.75) |                   |                   |
| C5-C6              | 0.55 (0.25, 0.81) | 0.58 (0.25, 0.81) |                   |                   |
| C4-C7              | 0.53 (0.25, 0.81) | 0.63 (0.32, 0.86) |                   |                   |
| C2-C5              | 0.48 (0.19, 0.75) | 0.68 (0.39, 0.91) |                   |                   |
| C2-C6              | 0.48 (0.19, 0.75) | 0.63 (0.32, 0.86) |                   |                   |
| C2-C7              | 0.45 (0.19, 0.75) | 0.63 (0.32, 0.86) |                   |                   |

AUC = Area Under the Curve; FA = Fractional Anisotropy; MD = Mean Diffusivity; PWM = Posterior White Matter; LWM = Lateral White Matter; AGM = Anterior Grey Matter; ^ = Intervertebral Disc Level Chosen in CSM Patient rather than Healthy Subject; CI = Binomial Confidence Interval

chosen as a control group for comparative purposes in DTI of CSM [5,8,12-18]. It is well known that DTI metrics in patients with CSM differ to those of healthy volunteers [6]. The variability in intervertebral disc levels chosen as designated controls in healthy volunteers may ultimately affect the magnitude of the difference in the FA and MD values between CSM patients and healthy volunteers. Specifically, depending on the disc segments chosen, the quantifiable degree of difference in FA and MD values may either be accentuated or mitigated, and may subsequently increase or decrease the discriminatory power of DTI in its ability to distinguish between controls and patients, respectively. This would correspondingly be reflected by higher and lower AUCs, respectively. In this study, using ROC analysis, a characterization of the influence of choosing differing segments did not demonstrate a significant effect on the discriminatory power, as suggested by the overlapping 95% binomial CIs of the AUCs among the various control groups. The lack of significant differences in AUCs in this study is likely limited by the small sample size, and is reflected by the wide confidence intervals in both directions. Nevertheless, there is evidence in the literature to suggest that the choice of intervertebral disc levels as a control group in healthy volunteers may significantly influence the ability of DTI metrics to discriminate between controls and CSM patients.

For example, FA values have been reported to decrease with caudal

progression through the cervical cord [8]. Given FA has been shown to decrease in CSM patients [6], utilizing intervertebral disc levels C5-C6 through C7-T1 in healthy volunteers as a control group, for example, may lead to an underestimation in the degree of difference in FA values between CSM patients and controls, particularly if the disc segment severely involved in CSM is in the upper cervical cord (e.g. C3-C4). Furthermore, the signal-to-noise ratio has been observed to be lower in the C4 to T1 segments, leading to an overestimation of FA values in healthy patients [19]. Therefore, in contrast to the former instance, utilizing lower cervical intervertebral disc levels in healthy volunteers as a control group may lead to an overestimation in the degree of difference in FA values between CSM patients and controls, and ostensibly and misleadingly increasing the discriminatory power of DTI in differentiating controls and CSM patients.

Designating upper cervical disc segments as a control group, such as C2-C3, may prove equally problematic, and may not necessarily provide more accurate comparisons of DTI metrics. For example, significant age-related decreases in FA in upper cervical disc segments have been reported in healthy volunteers, occurring in the absence of compression or atrophy, and is thought to reflect gliosis and other microstructural-related changes with age [5,19-22]. Additionally, stenosis and compression in cervical spondylosis often involve C4-C5 through C6-C7. Choosing disc segments in the control

group that are significantly cephalad to levels of compression seen in CSM may prove problematic, as they are then increasingly affected by the differential cranial-caudal effects on FA values. Consistent with factors complicating an accurate FA comparison, Uda et al. [7] reported the highest AUCs were demonstrated with MD, suggesting the diagnostic utility of MD may be superior to that of FA.

Moreover, in a meta-analysis, a significant decreased FA was noted at C2-C3 for CSM patients, a level often uninvolved in cervical spondylosis, and is thought to reflect demyelination and axonal damage [23]. Earlier studies made measurements in upper nonstenotic segments such as C2-C3 in CSM patients as a control group, rather than utilizing healthy volunteers [17,18], with the understanding that a prior study failed to show significant differences in FA and MD between healthy volunteers and nonstenotic segments of CSM patients [12]. Thus, using segments in which DTI changes may similarly occur in both stenotic and nonstenotic regions may serve poorly for comparative purposes.

A potential solution to address the dilemma of which cervical disc level(s) in healthy volunteers may be most optimal for comparative purposes is to perform level-to-level comparisons throughout the cervical cord. Currently, the majority of prior studies exclusively chose a single intervertebral disc level in CSM patients for comparative purposes: the level of maximal cord compression. In contrast, a few studies have performed a level-to-level comparison between patients and healthy subjects, regardless of the location of maximal compression. For example, Wen et al. [6] compared intervertebral disc level C2-C3 of patients to C2-C3 of healthy volunteers, and in similar fashion for C3-C7. In our prior study, similar level-to-level comparisons were performed between patients and healthy subjects from C2-C3 through C7-T1 [24]. Given changes in DTI metrics have been observed to occur not only at levels of compression but any level throughout the cervical spine [6,23], assessing on a level-to-level basis may provide a more representative and comprehensive evaluation of the severity of CSM. This approach may also mitigate the influence of differential cranial-caudal effects on FA value comparisons, as well as potentially additional unaccounted for and unintended effects inherent in DTI analysis for DTI metric comparisons.

Several limitations exist within this study. The main and most evident limitation is the small sample size. This likely played a considerable contributory role in the lack of significant differences in discriminatory power of the varying designated intervertebral disc levels. Such instance of an underpowered study without detectable significant differences may thus occur despite the possibility of a true difference in the population. The second limitation is the notable difference in age between those designated as controls and patients, and may thus have a confounding influence on the comparisons and results. As mentioned earlier, there is growing evidence of the influence of aging on FA within the cervical spinal cord, with several prior studies observing decreasing FA with age [5,19-22]. Because cervical spondylosis is a degenerative disorder, recruitment of healthy volunteers without substantial findings of cervical spondylosis and yet of comparable age as CSM patients may be difficult and unfeasible. Lastly, manual placement of ROIs is prone to intra- and inter-rater variability, raising considerable challenges in reliably reproducing DTI metrics for comparative purposes. Altogether, these limitations may mitigate the meaningful interpretation of our findings.

In summary, while the current study did not demonstrate significant differences in discriminatory power based on differing intervertebral disc levels chosen for designated control groups,

the small sample size may predominantly have accounted for such findings. Nevertheless, this study hopes to emphasize the mindful approach necessary in designating appropriate controls, which have been highly variable in prior studies, in evaluation of CSM with DTI. Given the current lack of understanding of such influences of inter-study variability of control groups on DTI metric comparisons in CSM, further investigation with a larger population is needed to assess the potential impact on DTI analysis and further our understanding of how to more accurately interpret DTI data in the evaluation of CSM.

## Ethical Approval

All procedures performed in studies involving human participants were in accordance with the ethical standards of the institutional and/or national research committee and with the 1964 Helsinki declaration and its later amendments or comparable ethical standards.

## Conflict of Interest

Izlem Izbudak has received research grants from Siemens Medical Solutions USA Inc. Oluwatoyin Idowu and Kevin Yuqi Wang declare no conflict of interest.

## References

1. Levine DN. Pathogenesis of cervical spondylotic myelopathy. *J Neurol Neurosurg Psychiatry*. 1997;62(4):334-40.
2. Singh A, Crockard HA, Platts A, Stevens J. Clinical and radiological correlates of severity and surgery-related outcome in cervical spondylosis. *J Neurosurg*. 2001;94(2):189-98.
3. Demir A, Ries M, Moonen CT, Vital JM, Dehais J, Arne P, et al. Diffusion-weighted MR imaging with apparent diffusion coefficient and apparent diffusion tensor maps in cervical spondylotic myelopathy. *Radiology*. 2003;229(1):37-43.
4. Hori M, Okubo T, Aoki S, Kumagai H, Araki T. Line scan diffusion tensor MRI at low magnetic field strength: feasibility study of cervical spondylotic myelopathy in an early clinical stage. *J Magn Reson Imaging*. 2006;23(2):183-8.
5. Mamata H, Jolesz FA, Maier SE. Apparent diffusion coefficient and fractional anisotropy in spinal cord: age and cervical spondylosis-related changes. *J Magn Reson Imaging*. 2005;22(1):38-43.
6. Wen CY, Cui JL, Liu HS, Mak KC, Cheung WY, Luk KD, et al. Is diffusion anisotropy a biomarker for disease severity and surgical prognosis of cervical spondylotic myelopathy?. *Radiology*. 2014;270(1):197-204.
7. Uda T, Takami T, Tsuyuguchi N, Sakamoto S, Yamagata T, Ikeda H, et al. Assessment of cervical spondylotic myelopathy using diffusion tensor magnetic resonance imaging parameter at 3.0 tesla. *Spine*. 2013;38(5):407-14.
8. Budzik JF, Balbi V, Le Thuc V, Duhamel A, Assaker R, Cotten A. Diffusion tensor imaging and fibre tracking in cervical spondylotic myelopathy. *European radiology*. 2011;21(2):426-33.
9. Jones JG, Cen SY, Lebel RM, Hsieh PC, Law M. Diffusion tensor imaging correlates with the clinical assessment of disease severity in cervical spondylotic myelopathy and predicts outcome following surgery. *AJNR Am J Neuroradiol*. 2013;34(2):471-8.
10. Nakamura M, Fujiyoshi K, Tsuji O, Konomi T, Hosogane N, Watanabe K, et al. Clinical significance of diffusion tensor tractography as a predictor of functional recovery after laminoplasty in patients with cervical compressive myelopathy. *J Neurosurg Spine*. 2012;17(2):147-52.
11. Bosma RL, Stroman PW. Characterization of DTI Indices in the Cervical,

- Thoracic, and Lumbar Spinal Cord in Healthy Humans. *Radiol Res Pract.* 2012;2012:143705.
12. Facon D, Ozanne A, Fillard P, Lepeintre JF, Tournoux-Facon C, Ducreux D. MR diffusion tensor imaging and fiber tracking in spinal cord compression. *AJNR Am J Neuroradiol.* 2005;26(6):1587-94.
  13. Wang W, Qin W, Hao N, Wang Y, Zong G. Diffusion tensor imaging in spinal cord compression. *Acta Radiol.* 2012;53(8):921-8.
  14. Xiangshui M, Xiangjun C, Xiaoming Z, Qingshi Z, Yi C, Chuanqiang Q, et al. 3 T magnetic resonance diffusion tensor imaging and fibre tracking in cervical myelopathy. *Clin Radiol.* 2010;65(6):465-73.
  15. Kerkovský M, Bednarík J, Dušek L, Sprláková-Puková A, Urbánek I, Mechl M, et al. Magnetic resonance diffusion tensor imaging in patients with cervical spondylotic spinal cord compression: correlations between clinical and electrophysiological findings. *Spine.* 2012;37(1):48-56.
  16. Rajasekaran S, Yerramshetty JS, Chittode VS, Kanna RM, Balamurali G, Shetty AP... The assessment of neuronal status in normal and cervical spondylotic myelopathy using diffusion tensor imaging. *Spine.* 2014;39(15):1183-9.
  17. Kara B, Celik A, Karadereler S, Ulusoy L, Ganiyusufoglu K, Onat L, et al. The role of DTI in early detection of cervical spondylotic myelopathy: a preliminary study with 3-T MRI. *Neuroradiology.* 2011;53(8):609-16.
  18. Song T, Chen WJ, Yang B, Hong-Pu Z, Jian-Wei H, Ming-Jin C, et al. Diffusion tensor imaging in the cervical spinal cord. *Eur Spine J.* 2011;20(3):422-8.
  19. Vedantam A, Jirjis MB, Schmit BD, Wang MC, Ulmer JL, Kurpad SN. Characterization and limitations of diffusion tensor imaging metrics in the cervical spinal cord in neurologically intact subjects. *J Magn Reson Imaging.* 2013;38(4):861-7.
  20. Agosta F, Laganà M, Valsasina P, Sala S, Dall'Occchio L, Sormani MP, et al. Evidence for cervical cord tissue disorganisation with aging by diffusion tensor MRI. *Neuroimage.* 2007;36(3):728-35.
  21. Lindberg PG, Feydy A, Maier MA. White matter organization in cervical spinal cord relates differently to age and control of grip force in healthy subjects. *J Neurosci.* 2010;30(11):4102-9.
  22. Van Hecke W, Leemans A, Sijbers J, Vandervliet E, Van Goethem J, Parizel PM. A tracking-based diffusion tensor imaging segmentation method for the detection of diffusion-related changes of the cervical spinal cord with aging. *J Magn Reson Imaging.* 2008;27(5):978-91.
  23. Guan X, Fan G, Wu X, Gu G, Gu X, Zhang H, et al. Diffusion tensor imaging studies of cervical spondylotic myelopathy: a systemic review and meta-analysis. *PLoS One.* 2015;10(2):e0117707.
  24. Wang KY, Idowu O, Thompson CB, Orman G, Myers C, Riley LH 3rd, et al. Tract-Specific Diffusion Tensor Imaging in Cervical Spondylotic Myelopathy Before and After Decompressive Spinal Surgery: Preliminary Results. *Clin Neuroradiol.* 2017;27(1):61-9.