



# Fully Automated Serial Volumetric 3 Dimensional Brain MRI Assesses Grey Matter Volumes and Rate of Progression in a Case of Primary Progressive Multiple Sclerosis

Ted Rothstein\*

Department of Neurology, George Washington University, USA

## Abstract

Focal Multiple Sclerosis lesions in white matter (WM) are easily detected with conventional MRI as they have inflammatory properties which generate contrast. However, the burden of WM lesions does not explain the extent of clinical and cognitive impairments that commonly occur in MS patients. It is established that grey matter (GM) axonal loss in MS occurs early and plays a key role in disease progression, disability and cognitive dysfunction. Recent studies in patients with Primary Progressive Multiple Sclerosis (PPMS) suggest that progression and disability correlate directly with GM atrophy. Given its seminal importance, it is critical to define the degree to which GM structures are affected in MS patients. A new advanced MRI post processing technique (NeuroQuant) employs fully automated 3 dimensional volumetric MRI analysis of GM structures and produces a reliable assessment of GM volumes. Serial studies can quantify progression and rate of change. Serial NeuroQuant images were obtained in a 42 year old male with PPMS over 39 months and showed significant volume reductions in cortical GM and deep nuclei. NeuroQuant imaging was able to establish the degree to which progression had occurred, and helped to clarify GM contributions to his cognitive and clinical deterioration. Serial NeuroQuant confirmed that loss of GM was more predictive of clinical deterioration than WM abnormalities, supporting conclusions already drawn by PPMS histopathology.

## OPEN ACCESS

### \*Correspondence:

Ted Rothstein, Department of Neurology, The George Washington University, 2150 Pennsylvania Ave, NW Suite 9-412, Washington, DC 20037, USA, Tel: 202-725-7985; Fax: 202-741-2721;

E-mail: trothstein@mfa.gwu.edu

Received Date: 09 Jun 2016

Accepted Date: 01 Nov 2016

Published Date: 15 Nov 2016

### Citation:

Ted Rothstein. Fully Automated Serial Volumetric 3 Dimensional Brain MRI Assesses Grey Matter Volumes and Rate of Progression in a Case of Primary Progressive Multiple Sclerosis. *Remed Open Access*. 2016; 1: 1026.

**Copyright** © 2016 Ted Rothstein. This is an open access article distributed under the Creative Commons Attribution License, which permits unrestricted use, distribution, and reproduction in any medium, provided the original work is properly cited.

**Keywords:** Grey matter analysis; Primary Progressive Multiple Sclerosis; Diagnostic Test assessment; Volumetric MRI

## Introduction

WM abnormalities often fail to explain the source of an MS exacerbation or the degree of cognitive and physical impairment that MS patients experience, which has been identified as the “clinico-radiological paradox” [1,2]. It has become increasingly evident that GM demyelination occurs early, is frequent and extensive in MS, and critical to the development of clinical and cognitive disability [3-6]. There is evidence that GM damage accelerates and is more extensive in progressive forms of MS [7-11]. Fisniku et al. [8] studied over 20 years a number of clinically isolated syndrome (CIS) MS patients and determined that gray matter atrophy was a more dependable predictor of disability than burden of white matter plaque. Until recently, GM lesions have been difficult to detect using conventional MR imaging techniques [12-14]. For example, only 5% of histopathological lesions in the cortex are identified with standard FLAIR and T2 sequences [15]. A variety of new advanced MRI techniques including high resolution 7 Tesla imaging, Rapid Acquired Gradient ECHO, double inversion recovery, and magnetization transfer have improved visualization of GM lesions not previously identifiable [16-41]. Unfortunately, only a small fraction of lesions identified histopathologically are identified with these techniques [15,16]. Recognizing the importance of GM pathology in MS, it is essential to have a reliable method for accurately measuring the degree of GM pathology in this disease. One promising new MRI post processing technique is fully automated 3 dimensional volumetric brain segmentation (NeuroQuant), which is proven to be accurate for quantitative volume analysis of GM structures [42]. Longitudinal imaging studies have been used to predict those patients with Mild Cognitive Impairment destined to develop Alzheimer’s disease and help define the progression of dementia [42-47]. To date there have been few longitudinal MRI studies that have assessed the degree or rate of progression of GM lesions in MS patients.

**Table 1:** Rate of Progression 2011-2015.

Structure	Oct. 2011 Volume (cm <sup>3</sup> )	Dec. 2013 Volume (cm <sup>3</sup> )	Jan. 2015 Volume (cm <sup>3</sup> )	2011-13 Percent Change	2013-15 Percent Change	2011-15 Overall Percent Change
Cortical Grey Matter	410.38	379.1	367.81	-7.62%	-2.98%	-10.37%
White Matter	403.67	454.12	420.49	+12.50%	-7.41%	+4.17%
Hippocampus	4.95	4.63	3.93	-6.46%	-15.12%	-20.61%
Inferior Lateral Ventricles	2.9	3.51	4.37	+21.03%	+24.50%	+50.69%
Amygdala	3.04	2.73	2.7	-10.20%	-1.10%	-11.18%
Caudate	4.89	4.65	4.23	-4.91%	-9.03%	-13.50%
Thalamus	8.83	8.35	7.55	-5.44%	-9.58%	-14.50%

I present a case report concerning a patient with PPMS who had a remarkable loss of volume in key GM structures over a period of 39 months, including cortical grey, hippocampus, thalamus, caudate, and amygdala, corresponding closely to his clinical and cognitive decline.

### Case Report

A 42 year old African American male developed progressive cognitive impairment, abnormal behaviors, dysarthric and scanning speech, diffuse 4 extremity ataxia and bilateral hand tremors over a period of 5 years. He would become angry inappropriately, was forgetful and could not be relied upon to eat or take medication. He had become disoriented in time and place, had disturbed immediate verbal recall, slowed information processing and dyscalculia. A recent EDSS score was 8.0 and MMSE score declined from 23 to 11 over this period. Serial brain MRIs revealed increases of discrete white matter hyper intensities on axial FLAIR confirming the presence of dissemination in space and time. Three NeuroQuant images were obtained over 39 months and showed- as a percent of total brain volume-reductions of: cortical grey matter 10.37%, bilateral hippocampal volumes 20.6%, bi-thalamic volumes 14.5%, bi-caudate volumes 13.5%, amygdala volumes 11.18% and while the inferior lateral ventricle volumes increased by 50.69%. The relative change in total WM showed an increase of 4.7% (Table 1) (Figures 1-6).

### Methods

Longitudinal 3 dimensional volumetric MR imaging studies were performed with an 8 channel phased array head coil. Images were processed using fully automated volumetric segmentation with a quantitative MR imaging software package (NeuroQuant v1.4, CorTechs Labs, San Diego, California) [42-46]. Image acquisition included a 3 plane localizer sequence and 3 dimensional volumetric T1 weighted gradient echo sequence acquired over an additional 7 minutes in a standard 1.5 Tesla General Electric imaging MRI unit. Image volumes obtained using NeuroQuant have been validated against manual segmentation and on the basis of those studies received approval for clinical use by the US Food and Drug Administration in measuring volumes of brain structures. The NeuroQuant quantitative MR imaging output compares a patient's regional brain volumes with age and gender matched normative database taken as a percentage of total intracranial volume [42].

### Discussion

WM Pathology has been the major focus of MS clinical assessment and research because of the ease of detection on MRI despite physical aspects such as fatigue, cognitive impairment, seizures, and physical disability which link to GM dysfunction. Moreover, WM abnormalities often fail to explain the source of an exacerbation or the

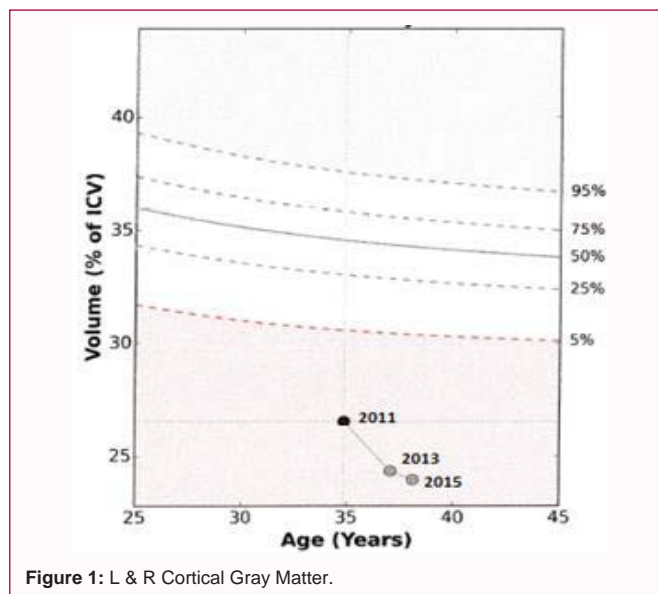


Figure 1: L & R Cortical Gray Matter.

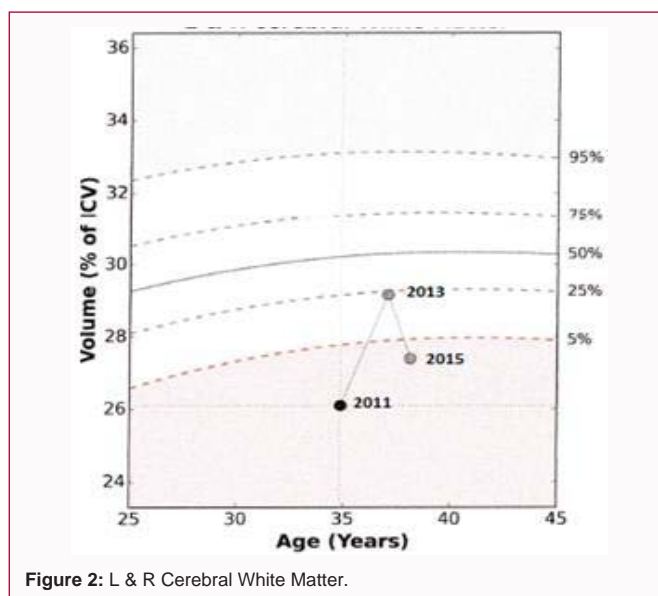
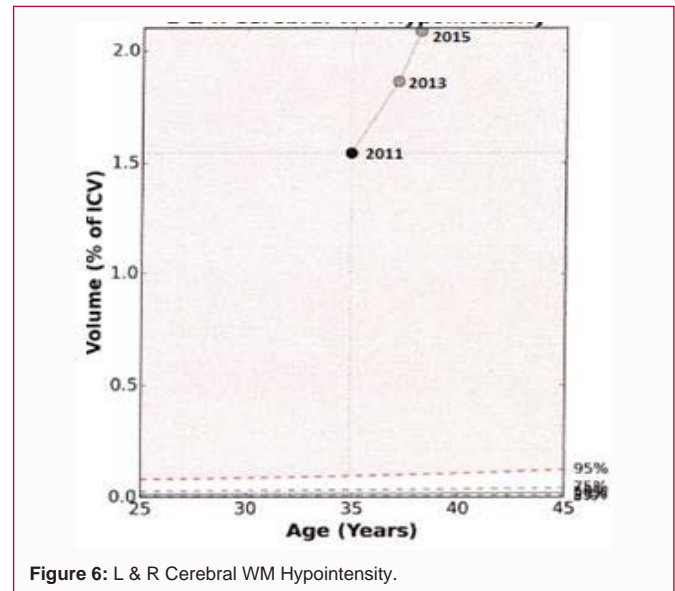
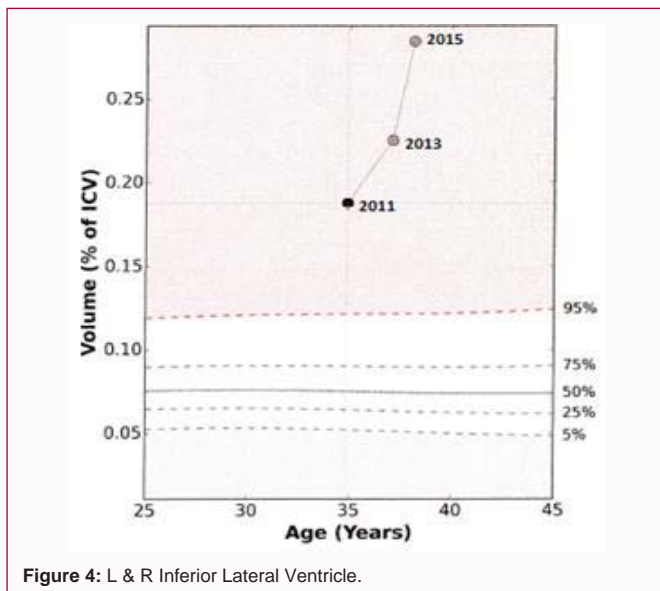
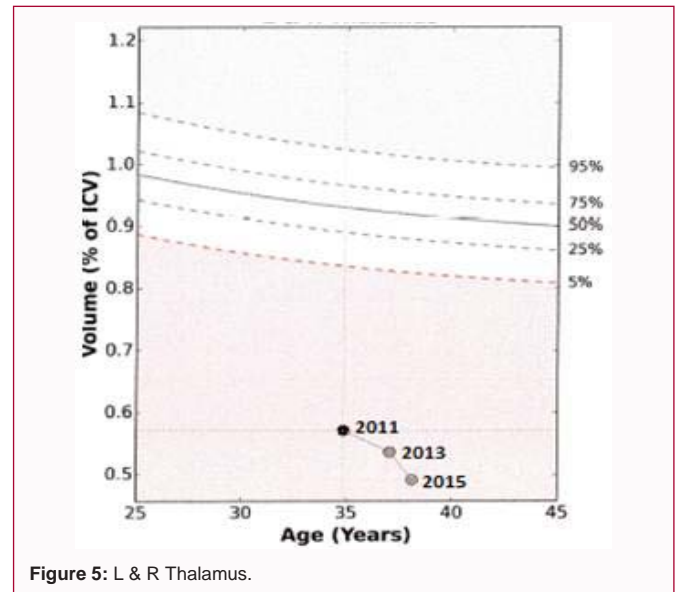
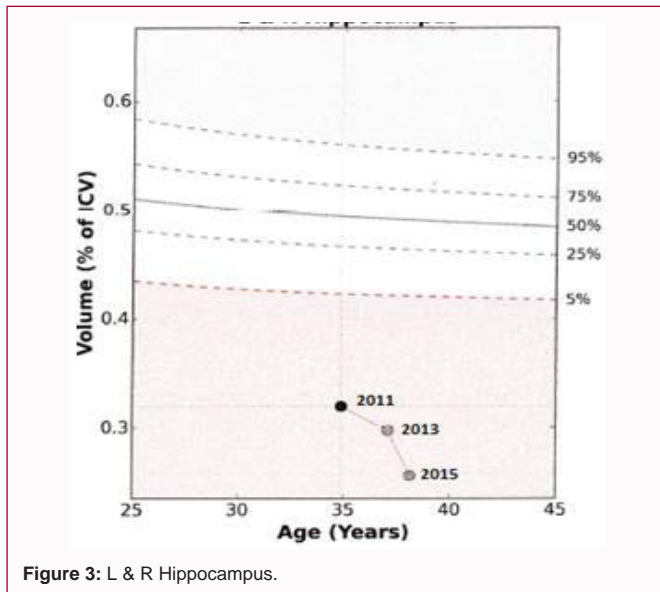


Figure 2: L & R Cerebral White Matter.

degree of clinical and cognitive impairments MS patients' experience. Extensive GM pathology has been shown to be a critical factor in clinical and cognitive impairment and may be the most important determinant of permanent disability [2-16]. Pathologic studies in MS have demonstrated widespread involvement of GM structures including the neocortex, hippocampus, thalamus, basal ganglia, cerebellum, and spinal cord [48-57].

Cortical lesions have been found to account for a greater



proportion of demyelination than WM lesions [22-35,58-64]. They are typically missed with conventional MRI and most of the new advanced MRI techniques are reported to detect only the “tip of the iceberg” [13-16]. NeuroQuant MRI technique can quantify GM cortical and deep nuclei volumes and can depict the rate at which damage produces volume reductions to these structures with serial studies [42-46].

Recent studies have reported substantial atrophy with neuronal loss in the hippocampus of MS patients [65-72]. The number and extent of lesions in the hippocampus also correlate with impaired visuospatial memory performance [66-68]. Geurts and colleagues collected hippocampal tissue samples from 19 patients with chronic MS and found that hippocampal demyelination was frequent and extensive [65]. Sicotte et al. [66] using high resolution MR imaging at 3T reported hippocampal atrophy was in excess of global brain atrophy in relapsing and secondary progressive MS (SPMS) and was associated with deficits in memory encoding and retrieval. The hippocampus is known to play a crucial role in episodic memory formation and retrieval, and cell loss can account for much of the

cognitive decline present in more than half of MS patients [73].

Houtchens et al. [74] used 3 dimensional volumetric MRI scans to assess a number of GM structures including thalamic volumes in 79 MS patients compared with 16 normal controls. They found a 16.8% reduction in thalamic volume in MS cases which correlated with impaired cognitive performance. Sepulcre et al. [5] used voxel based morphometric analysis to examine regional distribution of GM atrophy in 31 patients with PPMS and found bilateral thalamic atrophy compared with controls. There was also loss of GM in putamen, caudate, cortical, and infratentorial areas after 1 year follow up [5]. Minagar et al. [75] reviewed the underpinnings of thalamic damage in MS patients which resulted in cognitive decline, motor deficits, fatigue, pain syndromes, and oculomotor disturbances. In a pathologic study on distribution of GM demyelinating lesions in MS, Vercellino et al. [52] describe a case where thalamic demyelination was prominent, involving up to one third of the thalamus on coronal section. Rocca et al. [76] identified thalamic atrophy in MS patients using magnetization transfer MRI which correlated with long-term disability. Cifelli et al. [77] focused on the thalamic medial

dorsal nucleus on post mortem histopathologic analysis and used 3 dimensional magnetization-prepared fast gradient ECHO sequences in 14 SPMS patients and demonstrated about one third reduction in thalamic volumes compared to controls. Other studies by Zivadinov et al. [78,79] documented that thalamic atrophy was related to decreased information processing speed in MS.

Prinster et al. [25] using voxel based morphometry in 51 RRMS patients, found that caudate atrophy correlated with lesion load but not disease duration or clinical status. Bermel et al. [80,81] found bicaudate atrophy was 19% more extensive in MS patients, while increase in bicaudate ratio reflected subcortical atrophy and correlated with plaque lesion load and cognitive decline.

## Conclusion

Volume loss of cerebral cortex and deep GM structures have been identified as the key finding in patients with PPMS and correlates better with clinical and cognitive disability than white matter lesion load [3-16]. The importance of GM integrity makes it essential to have an accurate means of measuring the degree and rate of change of GM pathology. Fully automated three dimensional volumetric brain segmentation MR imaging has provided an accurate and reproducible means of measuring volumes of cortical grey and deep GM nuclei with an easily interpretable imaging technique [42-47]. Serial NeuroQuant studies in this case report documents the presence and rate of GM volume loss in specific structures such as cortical GM, hippocampus, thalamus, caudate, and amygdala over 39 months, which correlates closely with this patient's clinical and cognitive decline. These results warrant verification by studying additional MS patients with and without cognitive complaints and disability that is currently underway.

## Acknowledgement

The author is grateful for the technical assistance provided by GW Department of Neurology Research Associate Ms. Pooja Rajadhyaksha.

## References

- Barkhof F. The clinico-radiological paradox in multiple sclerosis revisited. *Curr Opin Neurol.* 2002; 15: 239-245.
- Bö L, Geurts JJ, van der Valk P, Polman C, Barkhof F. Lack of correlation between cortical demyelination and white matter pathologic changes in multiple sclerosis. *Arch Neurol.* 2007; 64: 76-80.
- Kitzelnigg A, Lucchinetti CF, Stadelmann C, Bruck W, Rauschka H, Bergman M, et al. Cortical demyelination and diffuse white matter injury in multiple sclerosis. *Brain.* 2005; 128: 2705-2712.
- Calabrese M, De Stefano N, Atzori M, Bernardi V, Mattisi I, Barachino L, et al. Detection of cortical inflammatory lesions by double inversion recovery magnetic resonance imaging in patients with multiple sclerosis. *Arch Neurol.* 2007; 64: 1416-1422.
- Sepulcre J, Sartre-Garriga J, Cercignani M, Ingle GT, Miller DH, Thompson AJ. Regional Gray Matter Atrophy in Early Primary Progressive Multiple Sclerosis. *Arch Neurol.* 2006; 63: 1175-1180.
- Morgen K, Sammer G, Courtney SM, Wolters T, Melchoir H, Belcher CR, et al. Evidence for a direct association between cortical atrophy and cognitive impairment in relapsing-remitting MS. *NeuroImage.* 2006; 30: 891-898.
- Geurts JJG. Is progressive multiple sclerosis a gray matter disease? *Ann Neurol.* 2008; 64: 230-239.
- Fisniku LK, Chard DT, Jackson JS, Anderson VM, Altmann DR, Miszkil K, et al. Gray Matter Atrophy is related to Long Term Disability in Multiple Sclerosis. *Ann Neurol.* 2008; 64: 247-254.
- Fisher E, Lee J-C, Nakamura K, Rudick RA. Gray Matter Atrophy in Multiple Sclerosis: A longitudinal Study. *Ann Neurol.* 2008; 64: 255-265.
- Geurts JJG, Barkhof F. Grey matter pathology in multiple sclerosis. *Lancet Neurol.* 2008; 7: 841-851.
- Khaleeli Z, Cercignani M, Audoin B, Ciccarelli O, Miller DH, Thompson AJ. Localized grey matter damage in early primary progressive multiple sclerosis contributes to disability. *NeuroImage.* 2007; 37: 253-261.
- Filippi M, Rocca MA, Benedict RH, DeLuca J, Geurts JJ, Rombouts SAR, et al. The contribution of MRI in assessing cognitive impairment in multiple sclerosis. *Neurology.* 2010; 75: 2121-2128.
- Seewan A, Vrenken H, Kooi E-J, van der Volk P, Knol DL, Polman CH, et al. Imaging the tip of the iceberg: visualization of cortical lesions in multiple sclerosis. *MultScler J.* 2011; 17: 1202-1210.
- Baskshi R, Thompson AJ, Rocca MA, Pelletier D, Dousset V, Barkhof F, et al. MRI in multiple sclerosis; current status and future prospects. *Lancet Neurol.* 2008; 7: 615-625.
- Geurts JJ, Bö L, Pouwels PJW, Castelijns JA, Polman CH, Barkhof F. Cortical lesions in multiple sclerosis: combined postmortem MR imaging and histopathology. *AJNR Am J Neuroradiol.* 2005; 26: 572-577.
- Geurts JJ, Blezer EL, Vrenken H, van der Toom A, Castelijns JA, Polman CH, et al. Does high-field MR imaging improve cortical lesion detection in multiple sclerosis? *J Neurol.* 2008; 255: 183-191.
- Kolasinski J, Stagg CJ, Chance SA, DeLuca GC, Esiri MM, Chang E-H, et al. A combined post-mortem magnetic resonance imaging and quantitative histological study of multiple sclerosis pathology. *Brain.* 2012; 135: 2938-2951.
- Filippi M, Rocca MA. MR imaging of multiple sclerosis. *Radiology.* 2011; 259: 659-681.
- Filippi M, Rocca MA, De Stefano N, Enzinger C, Fisher E, Horsfield MA, et al. Magnetic Resonance Techniques in Multiple Sclerosis. The Present and the Future. *Arch Neurol.* 2011; 68: 1514-1520.
- Lovblad K-O, Anzalone N, Dorfler A, Essig M, Hurwitz B, Kappos L, et al. MR Imaging in Multiple Sclerosis and Recommendations for Current Practice. *AJNR Am J Neuroradiol.* 2010; 31: 983-989.
- Poloni G, Minagar A, Haacke EM, Zivadinov R. Recent Developments in Imaging of Multiple Sclerosis. *The Neurologist.* 2011; 17: 185-204.
- Coebergh JAF, Roosendaal SD, Polman CH, Geurts JJ, van Woerkom TCAM. Acute severe memory impairment as a presenting symptom of multiple sclerosis: a clinical case study with 3D double inversion recovery MR imaging. *Multiple Sclerosis.* 2010; 16: 1521-1524.
- Nielsen AS, Kinkel R, Madigan N, Tinelli E, Benner T, Mainero C. Contribution of cortical lesion subtypes at 7T MRI to physical and cognitive performance in MS. *Neurology.* 2013; 81: 641-649.
- Tallantyre EC, Morgan PS, Dixon JE, Al-Radaideh A, Brookes MJ, Morris PG, et al. 3 tesla and 7 tesla MRI of multiple sclerosis cortical lesions. *J MagnReson Imaging.* 2010; 32: 971-977.
- Sethi V, Yousry TA, Muhlert N, Ron M, Golay X, Wheeler-Kingshott C, et al. Improved detection of cortical MS lesions with phase-sensitive inversion recovery MRI. *J NeurolNeurosurgPsychiat.* 2012; 83: 877-882.
- Schmierer K, Parkes HG, So PW, An SF, Brandner S, Ordidge RJ, et al. High field (9.4 tesla) magnetic resonance imaging of cortical grey matter lesions in multiple sclerosis. *Brain.* 2010; 133: 858-867.
- Hurley AC, Al-Radaideh A, Bai L, Aickelin U, Coxon R, Glover P, et al. Tailored RF pulse for magnetization inversion at ultra-high field. *MagnReson Med.* 2010; 63: 51-58.
- Mainero C, Benner T, Radding A, van der Kouwe I, Jensen I, Rosen BR, et

- al. *In vivo* imaging of cortical pathology in multiple sclerosis using ultra-high field MR. *Neurology*. 2009; 73: 941-948.
29. Kilsdonk ID, de Graaf WL, Lopez Soriano A, Zwanenburg JJ, Visser F, Kuijper JPA, et al. Multicontrast MR imaging at 7 T in multiple sclerosis: highest lesion detection in cortical gray matter with 3-D FLAIR. *Am J Neuroradiol*. 2013; 34: 791-796.
  30. Mougou O, Clemence M, Peters A, Pitiot A, Gowland PA. High resolution imaging of magnetization transfer and nuclear Overhauser effect in the human visual cortex at 7 T. *NMR Biomed*. 2013; 26: 1508-1517.
  31. Mougou OE, Coxon RC, Pitiot A, Gowland PA. Magnetization transfer phenomenon in the human brain at 7 T. *Neuroimage*. 2010; 49: 272-281.
  32. Lüsebrink F, Wollrab A, Speck O. Cortical thickness determination of the human brain using high resolution 3T and 7T MRI data. *Neuroimage*. 2013; 70: 122-131.
  33. Abdel-Fahim R, Mistry N, Mougou O, Blazejewska A, Pitiot A, Retkute R, et al. Improved detection of focal cortical lesions using 7 T magnetization transfer imaging in patients with multiple sclerosis *MultSclerRel Dis*. 2014; 3: 258-265.
  34. Geurts JGG, Roosendaal SD, Calabrese M, Ciccarelli O, Agosta F, Chard DT, et al. Consensus recommendations for MS cortical lesion scoring using double inversion recovery MRI. *Neurology*. 2011; 76: 418-424.
  35. Daams M, Geurts JGG, Barkhof F. Cortical imaging in multiple sclerosis: recent findings and 'grand challenges'. *Curr Opin Neurol*. 2013; 26: 345-352.
  36. Giacomini PS, Levesque IR, Ribeiro L, Narayanan S, Francis SJ, Pike GB, et al. Measuring demyelination and remyelination in acute multiple sclerosis lesion voxels. *Arch Neurol*. 2009; 66: 375-381.
  37. Vrenken H, Jenkinson M, Horsfield MA, Battaglini M, van Schijndel RA, Rostrup E, et al. Recommendations to improve imaging and analysis of brain lesion load and atrophy in longitudinal studies of multiple sclerosis. *J Neurol*. 2013; 260: 2458-2471.
  38. Prinster A, Quarantelli M, Lanzillo R, Orefice G, Vacca G, Carotenuto B, et al. A voxel-based morphometry study of disease severity correlates in relapsing-remitting multiple sclerosis. *Mult Scler*. 2010; 16: 45-54.
  39. Prinster A, Quarantelli M, Orefice G, Lanzillo R, Brunetti A, Mollica C, et al. Gray matter loss in relapsing-remitting Multiple Sclerosis. A voxel based morphometry study. *NeuroImage*. 2006; 29: 859-867.
  40. Ceccarelli A, Rocca MA, Pagani E, Colombo B, Martinelli V, Comi G, et al. A voxel-based morphometry study of gray matter loss in MS patients with different clinical phenotypes. *NeuroImage*. 2008; 42: 315-322.
  41. Nelson F, Poonawalla AH, Hou P, Huang F, Wolinsky JS, Narayana PA. Improved identification of intracortical lesions in multiple sclerosis with phase-sensitive inversion recovery in combination with fast double inversion recovery MR imaging. *AJNR Am J Neuroradiol*. 2007; 28: 1645-1649.
  42. Brewer JB. Fully-automated volumetric MRI with normative ranges: translation to clinical practice. *BehavNeurol*. 2009; 21: 21-28.
  43. McEvoy LK, Brewer JB. Quantitative structural MRI for early detection of Alzheimer's disease. *Expert Rev Neurother*. 2010; 10: 1675-1688.
  44. Heister D, Brewer JB, Magda S, Blennow K, McEvoy LK; Alzheimer's Disease Neuroimaging Initiative. Predicting MCI outcome with clinically available MRI and CSF Biomarkers. *Neurology*. 2011; 77: 1619-1628.
  45. Kovacevic S, Rafi MS, Brewer JB; Alzheimer's disease Neuroimaging Initiative. High-throughput, fully automated volumetry for prediction of MMSE and CDR decline in mild cognitive impairment. *Alzheimer Dis Assoc Disord*. 2009; 23: 139-145.
  46. Brewer JB, Magda S, Airriess C, Smith ME. Fully Automated Quantification of Regional Brain Volumes for Improved Detection of Focal Atrophy in Alzheimer Disease. *AJNR Am J Neuroradiol*. 2009; 30: 578-580.
  47. Jack CR Jr, Bernstein MA, Fox NC, Thompson P, Alexander G, Harvey D, et al. The Alzheimer's disease neuroimaging initiative (ADNI): MRI methods. *J MagnReson Imaging*. 2008; 27: 685-691.
  48. Geurts JGG, Barkhof F. Grey matter pathology in multiple sclerosis. *Lancet Neurol*. 2008; 7: 841-851.
  49. Filippi M, Preziosa P, Copetti M, Riccitelli G, Horsfield MA, Martinelli V, et al. Gray matter damage predicts the accumulation of disability 13 years later in MS. *Neurology*. 2013; 81: 1759-1767.
  50. Sanfillipo MP, Benedict RH, Sharma J, Weinstock-Guttman B, Bakshi R. The relationship between whole brain volume and disability in multiple sclerosis. A comparison of normalized gray vs. white matter with misclassification correction. *NeuroImage*. 2005; 26: 1068-1077.
  51. Stadelmann C, Albert M, Wegner C, Bruck W. Cortical pathology in multiple sclerosis. *Curr Opin Neurol*, 2008; 21: 229-234.
  52. Vercellino M, Plano F, Votta B, Mutani R, Giordana MT, Cavalla P. Grey Matter Pathology in Multiple Sclerosis. *J Neuropathol ExpNeurol*. 2005; 64: 1101-1107.
  53. Bö L, Geurts JJ, Mork S, van der Valk P. Grey matter pathology in multiple sclerosis. *Acta Neurol Scand Suppl*. 2006; 183: 48-50.
  54. Pirko I, Lucchinetti CF, Sriram S, Bakshi R. Gray matter involvement in multiple sclerosis. *Neurology*. 2007; 68: 634-642.
  55. Wegner C, Stadelmann C. Grey Matter Pathology and Multiple Sclerosis. *CurrNeurolNeurosci Rep* 2009; 9: 399-404.
  56. Nygaard GO, Walhovd KB, Sowa P, Chepkoech J-L, Bjørnerud A, Due-Tønnessen P, et al. Cortical thickness and surface area relate to specific symptoms in early relapsing-remitting multiple sclerosis. *MultScler J*. 2015; 21: 402-414.
  57. Staff N, Lucchinetti C, Keegan M. Multiple Sclerosis with predominant severe cognitive impairment. *Arch Neurol* 2009; 66: 1139-1143.
  58. Calabrese M, Filippi M, Gallo P. Cortical lesions in multiple sclerosis. *Nat Rev Neurol*. 2010; 6: 438-444.
  59. Papadopoulos D, Dukes S, Patel R, Nicholas R, Vora A, Reynolds R. Substantial Archaiocortical Atrophy and Neuronal Loss in Multiple Sclerosis. *Brain Pathol*. 2009; 19: 238-253.
  60. Kidd D, Barkhof F, McConnell R, Algra PR, Allen IV, Revesz T. Cortical lesions in multiple sclerosis. *Brain* 1999; 122: 17-26.
  61. Gilmore CP, Donaldson I, Bö L, Owens T, Lowe J, Efgangelou N. Regional variations in the extent and pattern of grey matter demyelination in multiple sclerosis: a comparison between the cerebral cortex, cerebellar cortex, deep grey matter nuclei and the spinal cord. *J Neurol Neurosurg Psychiatry*. 2009; 80: 182-187.
  62. Wegner C, Esiri MM, Chance SA, Palace J, Mathews PM. Neocortical neuronal, synaptic and glial loss in multiple sclerosis. *Neurology*. 2006; 67: 960-967.
  63. Chen JT, Narayanan S, Collins DL, Smith SM, Matthews PM, Arnold DL. Relating neocortical pathology to disability progression in multiple sclerosis using MRI. *NeuroImage*. 2004; 23: 1168-1175.
  64. Charil A, Dagher A, Lerch JP, Zijdenbos AP, Worsley KJ, Evans AC. Focal cortical atrophy in multiple sclerosis: Relation to lesion load and disability. *NeuroImage*. 2007; 34: 509-517.
  65. Geurts JJ, Bö L, Roosendaal S, Hazes T, Daniels R, Barkhof F, et al. Extensive Hippocampal Demyelination in Multiple Sclerosis. *J Neuropath Exp Neurol*. 2007; 66: 819-827.
  66. Sicotte NL, Kern KC, Giesser BS, Arshanapalli A, Shultz A, Montag M, et al. Regional hippocampal atrophy in multiple sclerosis. *Brain*. 2008; 131: 1134-1141.
  67. Longoni G, Rocca MA, Pagani E, Riccielli GC, Colombo B, Rodegher M,

- et al. Deficits in memory and visuospatial learning correlate with regional hippocampal atrophy in MS. *Brain Struct Funct.* 2015; 220: 435-444.
68. Bird CM, Burgess N. The hippocampus and memory: insights from spatial processing. *Nat Rev Neurosci.* 2008; 9: 182-194.
69. Roosendaal SD, Hulst HE, Vrenken H, Feenstra H, Castelijns JA, Barkhof F, et al. Structural and functional hippocampal changes in multiple sclerosis patients with intact memory function. *Radiology.* 2010; 255: 595-604.
70. Benedict RHB, Ramasamy D, Munschauer F, Weinstock-Guttman B, Zivadinov R. Memory impairment in multiple sclerosis: correlation with deep grey matter and mesial temporal atrophy. *J NeurolNeurosurg Psychiatry.* 2009; 80: 201-206.
71. Papadopoulos D, Dukes S, Patel R, Nicholas R, Vora A, Reynolds R. Substantial Archæocortical Atrophy and Neuronal Loss in Multiple Sclerosis. *Brain Pathol.* 2009; 19: 238-253.
72. Roosendaal SD, Moraal B, Vrenken H, Castelijns JA, Pouwels PJ, Barkhof F, et al. *In vivo* MR imaging of hippocampal lesions in multiple sclerosis. *J Magn Reson Imaging.* 2008; 27: 726-731.
73. Squire LR, Stark CE, Clark RE. The medial temporal lobe. *Annu Rev Neurosci.* 2004; 27: 279-306.
74. Houtchens MK, Benedict RHB, Killiany R, Sharma J, Jaisani Z, Singh B, et al. Thalamic atrophy and cognition in multiple sclerosis. *Neurology.* 2007; 69: 1213-1223.
75. Minagar A, Barnett MH, Benedict RHB, Pelletier D, Pirko I, Sahraian MA, et al. The thalamus and multiple sclerosis. Modern views on pathologic, imaging and clinical aspects. *Neurology.* 2013; 80: 211-219.
76. Rocca MA, Mesaros S, Pagani E, Sormani MP, Comi G, Filippi F. Thalamic Damage and Long-term Progression of Disability in Multiple Sclerosis. *Radiology.* 2010; 257: 463-469.
77. Cifelli A, Arridge M, Jessard P, Esiri MM, Palace J, Matthews PM. Thalamic Neurodegeneration in Multiple Sclerosis. *Ann Neurol.* 2002; 52: 650-653.
78. Batista S, Zivadinov R, Hoogs M, Bergsland N, Heininen-Brown M, Dwyer M, et al. Basal ganglia, thalamus and neocortical atrophy predicting slowed cognitive processing in multiple sclerosis. *J Neurol.* 2012; 259: 139-144.
79. Zivadinov R, Bergsland N, Dolezal O, Hussein S, Seidl Z, Dwyer MG, et al. Evolution of Cortical and Thalamus Atrophy and Disability Progression in Early Relapsing-remitting MS during 5 years. *AJNR Am J Neuroradiol.* 2013; 34: 1931-1939.
80. Bermel RA, Innus MD, Tjoa CW, Bakshi R. Selective caudate atrophy in multiple sclerosis: a 3D MRI parcellation study. *NeuroReport.* 2003; 14: 335-339.
81. Bermel R, Bakshi R, Tjoa C, Puli SR, Jacobs L. Bicaudate ratio as a Magnetic Resonance Imaging marker of brain atrophy in Multiple Sclerosis. *Arch Neurol.* 2002; 59: 275-280.