



Does Oral Anticoagulant Therapy (OAT) Play a Key Role in Triggering and Maintaining Calciphylaxis? A Case Report Proposing a New Etiological and Nosological Review

Murtas S¹, Palomba M², Cozzolino M³ and Bolasco P^{1*}

¹Department of Nephrology and Dialysis, ASL of Cagliari, Italy

²Department of Public Surgery, ASL of Cagliari, Italy

³Department of Health Sciences, University of Milan, Italy

Abstract

Calcific uremic arteriopathy (CUA) is a rare but very serious morbid condition often observed during secondary hyperparathyroidism (HPTS). CUA affected patients by advanced chronic kidney disease (CKD). The Authors report a clinic case of a 63-year female diabetic patient on chronic hemodialysis that suddenly showed progressive necrotic cutaneous lesions similar to CUA. The status HPTS was in good control. This case led the authors to consider different etiological causes especially when vascular calcification. In the patient the main noxae could be the anticoagulant oral therapy (AOT) together smoking and inflammation induced by a severe malnutrition. Therapies proposals were sodium thiosulfate, based amino acids nutrition, an accurate and constant surgical medication of necrotic injuries. After the complete healing of skin lesions and good correction of nutritional status, the Authors asserted that OAT especially if associated with malnutrition smoking and diabetes can lead to necrotic lesions similar but not classifiable as calciphylaxis.

Keywords: Calcific uremic arteriopathy; Calciphylaxis; Secondary hyperparathyroidism

Case Presentation

A 63-year-old white Caucasian woman female showed rapidly extending ischaemic-necrotic lesions to the lower limbs. She had history of smoking and especially she was swallowing anticoagulant oral therapy based on acenocumarol by paroxysmic fibrillation. A skin biopsy showed a vasculitis with leukocytoclastic features without any vessel calcifications. At the beginning the diagnosis was calciphylaxis for the typical plurime skin necrosis features. Her laboratory data are as follows: serum parathyroid hormone (PTH), 260 pg/mL; ionized calcium, 4.2 mg/dL; serum phosphorus, 4.3 mg/dL; ANCA and ANA: negative; coagulation Free Protein S repeatedly low <68%; serum albumin, 3.2 g/dL. Which risk factors was determinant? Which treatment strategies should be considered? Would this disease be considered a validate calciphylaxis?

Introduction

Patients with chronic kidney failure (CKD) develop extra skeletal calcifications causing increased vascular stiffness, and much more risks of cardiovascular disease and increased mortality [1]. An increasing number of risk factors for vascular calcification are involved CKD: uremic status itself, the chronological age, sex, inflammation, abnormalities of mineral metabolism, concomitant diseases such as diabetes and blood hypertension [2]. Calcific uremic arteriopathy (CUA), more commonly, although at times inappropriately known as calciphylaxis, is a rare morbid condition manifested prevalently, although not exclusively, in patients affected by advanced chronic kidney disease (CKD) [3-7]. CUA is a severe, potentially fatal, and highly disabling disorder affecting approximately 1- 4% of the population with CKD [3] with a high mortality rate in approx. 60-80% of patients [8]. The mortality rate almost doubles in subjects presenting with ulcerative skin lesions. Death is mainly due to sepsis following infection of the necrotic skin lesions. Overall estimated survival rates at 1 and 5 years are 45% and 35%, respectively.

The clinical picture is characterized by painful skin lesions that tend to necrotize with subsequent

OPEN ACCESS

*Correspondence:

Piergiorgio Bolasco, Department of Nephrology, Territorial Unit of Nephrology and Dialysis, ASL of Cagliari, via Turati 4/C1, 09045 Quartu Sant'Elena (CA), Italy, Tel: +390706097335; Fax: +390706097340; E-mail: pg.bolasco@tin.it

Received Date: 18 May 2016

Accepted Date: 28 Oct 2016

Published Date: 15 Nov 2016

Citation:

Murtas S, Palomba M, Cozzolino M, Bolasco P. Does Oral Anticoagulant Therapy (OAT) Play a Key Role in Triggering and Maintaining Calciphylaxis? A Case Report Proposing a New Etiological and Nosological Review. *Remed Open Access*. 2016; 1: 1025.

Copyright © 2016 Bolasco P. This is an open access article distributed under the Creative Commons Attribution License, which permits unrestricted use, distribution, and reproduction in any medium, provided the original work is properly cited.

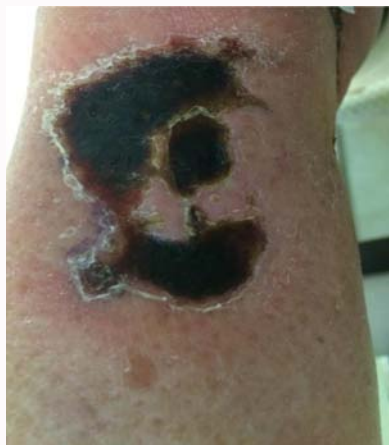

Figure 1: Necrotic lesions of left lower limb.

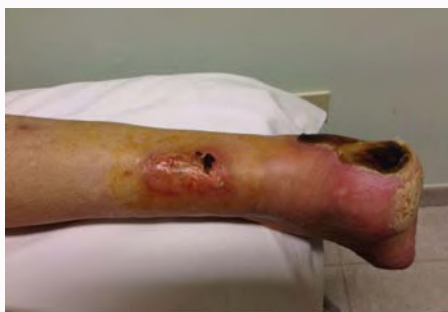

Figure 2: Necrotic lesions of right lower limb.

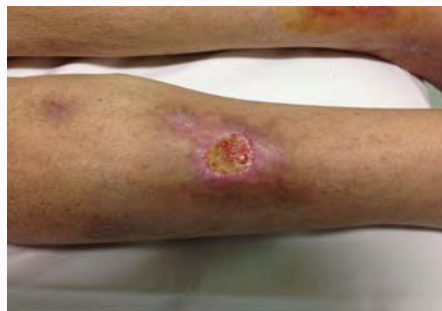

Figure 3: Initial healing of lesion of left leg after several specific medication: note absence of necrosis and appearance of granulation tissue (yellow layer).

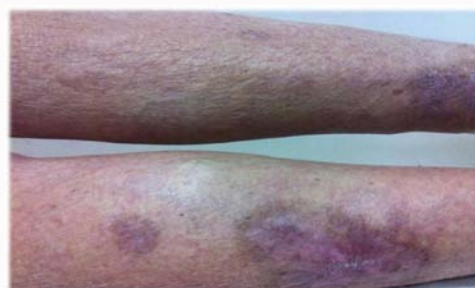

Figure 4: Complete healing of lesion; skin scars remain.

ulcers or gangrene, at times requiring amputation (Figure 1). The development of infections resulting in sepsis or death is a frequent occurrence.

Regrettably, the etiopathogenesis of CUA remains largely unknown, and the numerous pathogenetic hypotheses put forward tend not only to complicate treatment but also to render it somewhat empirical [6].

Indeed, CUA is a complex disorder generated by a multi-factorial aetiology. With a view to taking into consideration further hypotheses and etiological causes, as well as to avoid an inappropriate nosological generalization of the term “calcyphilaxis” (Phylakterion: safeguard, such as a tissue hypersensitivity reaction to calcium precipitation), it would like to highlight alternative clinical hypothesis inspired by our clinical case [9].

Clinical aspects, ethiological and diagnosis factors

In CUA the skin lesions are manifested in a characteristic manner and present a singular evolution phases. After pruritus the potential concomitant presentation of bullous alterations is indicative of the future onset of necrosis. At more advanced stages the affected areas extend and transform into hard black eschars with a tendency towards deep ulceration (Figure 2), at times reaching the muscle fascia. Gangrene may be observed (although amputation is rarely required) in the fingers and toes, and frequently in the penis. In case of healing it could have a progressive regression of the lesions thanks to frequent and accurate medications with removal of necrotizing lesions and afterwards, such as our clinic case, the appearance of granulation tissues until a full scar formation (Figure 3 and 4). Numerous dermatological conditions should be taken into account

during the initial stages. Differential diagnosis should be undertaken prevalently with: antiphospholipid syndrome, radiation arteritis, vasculitis, dystrophic calcification, cholesterol embolism, panniculitis, purpura fulminans, warfarin necrosis, heparin necrosis, nephrogenic systemic fibrosis, cutaneous anthrax, gangrenous pyoderma, oxalate arthropathy, obliterating arteriosclerotic vascular disease, [10,11] (Table 1). In the present case we excluded the CKD-MBD with vascular calcifications of secondary hyperparathyroidism (SHPT). Accordingly, we focussed our search on causes other than those routinely described in literature [9] summarized in table 1. In fact although the mechanisms pathogenesis of the process of vascular calcification is not fully defined, it isn't generally accepted just a passive process deposition of phosphate and calcium crystals. But a process actively and finely tuned to the level of the arterial wall, involving both endothelial cells, smooth muscle cells of vascular tunica media, vascular smooth muscle cells (VSMCs). In pathological conditions such as CKD, however, can change the VSMCs phenotype and it could turn into cells very similar to osteoblasts. The VSMCs synthesize proteins that are involved in the mechanisms of prevention of vascular calcification; in fact Protective Anti-Calcifying like the Matrix GLA protein (MGP) is one the most important key in preventing vascular calcification [12].

Given the relative rarity of calcyphilaxis there are no systematic analyzes of standardized diagnostic tests. Biomarkers and radiological tests, non invasive imaging tools (for example, simple x-rays and bone scans) and circulating Fetuin A have been reported to help in the diagnosis of calcyphilaxis. However, none of these instruments have been systematically evaluated and are not recommended for clinical use at this time [5,13-18]. Laboratory tests should highlight the potential risk factors: renal function, parameters of mineral metabolism such as serum calcium and phosphorus, alkaline phosphatase, intact PTH, and 25-hydroxyvitamin D, assessment of liver function and the evaluation of the usual inflammatory and

Table 1: Differential diagnosis of necrotic skin lesions in hemodialysis patient.

| | True Calciphylaxis | Calciphylaxis-like |
|---|---|--|
| Phases | 1) pruritus, 2) cutaneous laminar erythema, 3) painful ulceration, 4) necrosis. | likely in OAT skin necrosis but different onset outcome: dystrophic calcification, cholesterol embolism, panniculitis, purpura fulminans, nephrogenic systemic fibrosis, cutaneous anthrax, oxalate arteriopathy gangrenous pyoderma, obliterating arteriosclerotic vascular disease, antiphospholipid syndrome, radiation arteritis; |
| Hyperparathyroidism | especially in low and high turnover bone disease; | no influence on the diagnosis |
| Different limits | a) Distal: lower extremities b) proximal: trunk, thighs (especially fat), buttocks, abdomen, penis; (more than two skin pain ulcers) | likely in OAT skin necrosis but differences in: dystrophic calcification, cholesterol embolism, injection site necrosis in heparin necrosis, nephrogenic systemic fibrosis, nephrogenic systemic, oxalate arteriopathy, gangrenous pyoderma, cutaneous anthrax fibrosis, obliterating arteriosclerotic vascular disease, antiphospholipid syndrome, radiation arteritis. |
| Histomorphological findings | inside tunica media and internal of small/medium size vessels mural and extravascular calcifications with thrombosis and often concentric stenosis; | no vessel calcifications in all pathology except but different in: calcification histomorphology in dystrophic calcification , histological differences in rare calcification panniculitis, obliterating arteriosclerotic vascular disease, antiphospholipid syndrome, radiation arteritis; |
| Pathognomic and/or hematological and microbiological image study | nothing | in several pathologies there are specific markers like: vasculitis, allergic data, nephrogenic systemic fibrosis gadolinium-linked, cutaneous anthrax, gangrenous, oxalate arteriopathy pyoderma, antiphospholipid syndrome; |

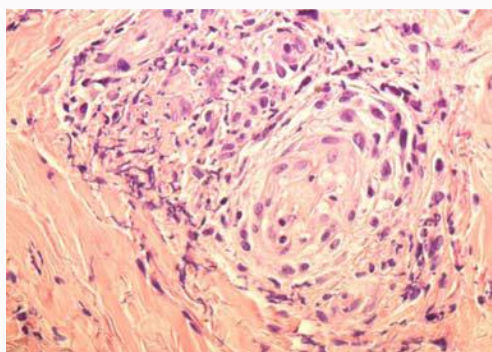


Figure 5: No evident vascular calcification with von Kossa stain; note vasculitis reaction of surrounding and inside wall vessels.

infectious analysis, evaluation of coagulation (prothrombin time and partial thromboplastin time, protein C, S antithrombin III and antiphospholipid antibodies) and specific checks in case of suspect of an immunological pathology, lipids abnormalities and others.

Risks and benefits of skin biopsy

Skin biopsy is a minimally invasive intervention that is achieved under local anesthesia inside of the surgeries studies, thus without the need to resort to hospitalization. There are four different types of this intervention depending on the portion of the skin removed and the methodology by which is taken: Excisional: in this case it is removed the entire portion of the skin affected by the pathology is suspected; Incisional: it is taken a diamond of skin; Punch: it is extracted a small portion of skin with an engraving cylinder; Shave: come off a thin flap of skin with tangential cut. Skin biopsy is very necessary in hemodialysis patients when there are more than, two painful non treatable skin ulcers irrespective of their localization [17]. The risks of biopsy may be: ulcerations, superimposed infection, spread of new lesions, haemorrhages and further necrosis induction; for these reasons it is necessary a monitoring with frequent medications of the wound-biopsy under antibiotics coverage especially against Staphylococcus families. Because the histopathological pathognomonic and ethimological findings is the calcification of the middle layer of the wall of arterioles showed only by silver nitrate (method "Von Kossa") or with red Alizarin, the biopsy is the only way to define a necrotic lesion such a " true calciphylaxis" (Figure 5) and to exclude other entities such as vasculitis.

The risk is tiny but very important rather than a rough diagnosis

and so an unsuccessful specific therapy. Calciphylaxis comprises two separate processes, firstly a pre-existent and/or transitory calcification of subcutaneous arterioles, and second infarctions of subcutaneous adipose tissue (panniculus adiposus) and skin [19]. Although subtle, perieccrine calcification may aid the diagnosis of calciphylaxis in settings in which typical vascular and extravascular calcifications have not been identified. However, the true pathognomic role of skin biopsy remains uncertain [20,21].

Frequent etiological factors

Secondary hyperparathyroidism or high turnover bone disease:

The impellent need for close monitoring of mineral metabolism is well acknowledged: maintenance of the calcium-phosphorus product <55, phosphorus ranging between 2.7 and 4.6 mg/dL. The administration solely of non-calcium based phosphate binders containing sevelamer and lanthanum carbonate is paramount. PTH levels are regulated by means of cinacalcet administration and by avoiding vitamin D and derivatives.

Undeniably, the onset of a large number of cases may be SHPT-linked; in our opinion, this definition should be limited solely to severe cases of CKD-MBD [22].

Low bone turnover disease: In the German calciphylaxis registry (www.calciphylaxie.de) a total of 253 patients had currently been included from 2006 to 2015; in 217 patients KDIGO target were 8% above range, 47% within range, and 47% below during calciphylaxis manifestation. There is a prevalence of female gender. This observation could mean that patients with a dynamic bone disease had a more risk of vascular calcification rather than these with high bone turnover disease but phosphorus in 217 patients has a great importance (KDIGO target 60% above, 34% within and 6% below) [23].

Bad Nutrition: Recent clinical and experimental data have shown how the protein metabolism is largely impaired in patients with chronic diseases such as heart failure [9,24,25].

Smoking: is considered a major risk factor for cardiovascular events in the general population. A prospective study has previously demonstrated an increased incidence of new-onset congestive heart failure, new-onset peripheral vascular diseases, and mortality among dialysis patients who smoke [26]. The increased risk of cardiovascular events may result from a higher level of fibrinogen and a higher systolic blood pressure in smokers than in non-smokers on dialysis. A meta-analysis also showed a significantly higher risk of mortality in

dialysis patients who smoke. These studies confirm that the patients who are current smokers are associated with increased mortality. The impact of smoking on mortality found in our study, HR=19.3, is much higher than that reported previously. Vascular dysfunction induced by smoking is initiated by reduced nitric oxide (NO) bioavailability and further by the increased expression of adhesion molecules and subsequent endothelial dysfunction. Smoking-induced increased adherence of platelets and macrophages provokes the development of a procoagulant and inflammatory environment [27]. Our finding supports the K-DOQI guidelines advocating regular counselling and encouragement for ESRD patients to stop smoking.

Role of anticoagulant therapy

In our case the use of OAT [28] was decisive, with smoking and inflammation-malnutrition acting as aggravating factors. Indeed, the most well-known vitamin K-dependent proteins (KDPs) are coagulant factors II, VII, IX, and X. In Brandenburg communication [23] by German Registry Analysis 2015 the beyond of 50% of patients assumed vitamin K antagonist but it didn't know how many patients were made the histological calcification pattern. By interfering with this carboxylation process, warfarin and/or acenocumarol have become the mainstay of anticoagulant therapy. In particular, two important VKDPs, Matrix Gla protein (MGP) and Growth Arrest Specific gene 6 (Gas-6) protein were involved [29]. The importance of the roles played by these proteins in vascular biology is currently undergoing extensive investigation. MGP acts primarily as a vascular calcification inhibitor. Gas-6 affects vascular smooth muscle cell movement and apoptosis. Together, these proteins constitute a new mechanism of local vascular regulation, in which the blood vessel defends itself against injury and participates in self-repair. A failure of these local mechanisms might at times be observed, although not necessarily tending towards vascular calcification [30]. The MGP is part of the family of proteins dependent on vitamin K, is synthesized by chondrocytes and by VSMCs and requires a gamma-carboxylation post-translational activity to reach a complete biological action. Warfarin is a vitamin K antagonist that interferes with the activation of the MGP precisely in this gamma-glutamyl carboxylation [31]. Vascular smooth muscle cells develop apoptotic bodies prior to forming calcium crystals; apoptosis may thus represent the critical first step in the process, although calcification may be a secondary, although not mandatory, phenomenon of dying cells [32]. However, a high clinical suspicion should be maintained, and adequate therapies, particularly with thiosulfate, implemented even when skin biopsy fails to confirm the involvement of vascular calcification [33]. Skin necrosis being TAO is also a known side effect. This rare complication usually occurs between the third and the eighth day therapy, and is caused by extensive thrombosis of the veins and capillaries of the subcutaneous adipose tissue. It manifests itself, especially at the expense of areas with abundant subcutaneous fat, such as breasts, buttocks, thighs, abdomen and it is little discernable to the true calciphilaxis. The patients who have genetic deficiency of protein C and S, antithrombin III, activated protein C resistance with or without the factor V Leiden mutation, the mutation G20210A of prothrombin, the antiphospholipid syndrome, seem most at risk. Histologically detects the occlusion of the capillaries subcutaneous and dermal by fibrin thrombi in the absence of a frank vasculitis with little or no deposit of the complement C3 into the dermoepithelial junction. The administration of vitamin K and heparin may prevent progression to frank necrosis, otherwise you need surgical treatment. There is still no adequate clinical experience in patients

undergoing hemodialysis using new oral anticoagulant that directly inhibit thrombin (dabigatran) or factor X a such as rivaroxaban and apixaban [34].

Rule of Therapies

Sodium thiosulfate (STS)

The proposed mechanism of action for STS is not yet fully known; the drug however appears to be capable of dissolving calcium salts deposited in tissues, transforming them into soluble calcium thiosulfate. Doses vary from 5 to 25 grams i.v three or four times a week for a period ranging from 6 to 24 months. However, the efficacy of thiosulfate may also be independent of the protective effect of crystal load, and at least in part due to its antioxidant properties [35]. Furthermore, the vasodilatory action of sodium thiosulfate on arterial circulation should not be underestimated [36].

Nutrition

The great important of bad nutrition explaining the increasing interest in a mixture of Essential Amino Acids (AEE) which has proved to be particularly useful in treating the aminoacidic "quake" typical of uremic status. This mixture is composed with leucine, lysine, isoleucine, valine, threonine, cystine, histidine, phenylalanine, methionine, tyrosine and tryptophan. The stimulatory mechanism of protein synthesis is attributable to the stimulation of the ancestral pathway m-TOR-kinases independently by insulin. This pathway could mainly activated in conditions of insulin-resistance as can be seen during the course of chronic renal failure. The mixture of amino acids investigated is particularly rich in branched-chain amino acids which are transported to the liver for gluconeogenic purposes and to the intestine as energetic substrate strong stimulators of glutamine and alanine synthesis [25]. However, the extent of impairment is frequently underestimated or ignored by clinicians, who fail to consider the possibility of prescribing amino acid therapy, thus resulting in a progressive loss of proteins in the body, increased morbidity, hospital stay and mortality. In the same way as patients with chronic heart failure, a considerable number of hemodialysis patients may be affected by muscular under perfusion, consequently resulting in severe impairment of enzyme mitochondrial activity and difficulty to resynthesize proteins especially for cells designated to the local and systemic immunological defence [38]. Moreover, the above mentioned literature has provided ample demonstration that the highest degree of penetration and intracellular insulin action is achieved by essential amino acids. Unfortunately, although the above has been repeatedly confirmed in cardiological and neurological literature, there has to date been a scarcity of interest from nephrologists [39,40].

Surgical medication

A multidisciplinary approach should be adopted both in the case of CUA-induced and other types of necrotizing lesions, with particular focus on the local treatment of skin lesions aimed at preventing the onset of local and/or systemic infection. Additionally, strict metabolic monitoring should be established in an attempt to halt the inevitable hypercatabolism produced by inflammation and reactivate the immune response compromised by malnutrition [37-39]. Medication represents one of the fundamental issues in healing this type of lesion; one of the best are TIME rule procedures (acronym of Tissue, Infection, Moisture Imbalance, Epidermal margin) should be rigorously applied [40]. The lesion should be combated both systemically and locally through the regenerating action of the

amino acids, particularly in diabetes. Diabetic patients may benefit considerably from use of essential amino acids, which promote cell sensitivity to the effect of exogenous and/or endogenous insulin [25]. Essential amino acid-based creams composed by glycine, L-proline, L-leucine and L-lisine may represent one of the key players in healing lesions by regenerating granulation tissues in the presence of an evident state of malnutrition. An inappropriate use of disinfectants inside of the lesion should be avoided and may result in necrosis of the abovementioned granulation tissues pivotal to the regeneration of all overlying cutaneous layers.

Calcimimetic

In the EVOLVE trial 24 of 3,861 enrolled patients developed calciphylaxis: six in cinacalcet arms and 18 in the placebo group. Cinacalcet could produce a 69%–75% of therapeutic risk reduction by cinacalcet [41].

Other therapeutic strategies

The confirmation of utility of bisphosphonate treatment lack the support of relevant comparative studies [42]. The positive effect of hyperbaric oxygen therapy remains to be confirmed, and the potential risk of eliciting tissue superoxide mechanisms assessed; further studies should be carried out to confirm the significance of the effect produced on tissues and cells by an excess of O₂ [43]. Intensifying dialytic therapy could be a double-edge sword because of the probable danger due to the balance by dialysate/infusate calcium concentration and it don't exist confirmation studies at the moment.

Conclusion

An extensive experience in the field has led us to consider a wide range of diagnostic and therapeutic horizons (Table 1). In numerous cases reported in literature skin biopsies were not carried out and/or the presence of vascular calcifications demonstrated; likewise, no reference was made to the use of drugs routinely prescribed in OAT. Fortunately it was recently added to the web network the European register on calciphylaxis (www.calciphylaxis.net). It would take into account and emphasized important data such: OAT, nutritional status (BMI, albumin and serum total protein) smoke and could be begun made on evidence a sub-classification different of CUA to classify in several clinical cases the term of "real calciphylaxis". In fact in our case OAT could be considered a triggering and/or maintaining cause of the ischemic lesions. In some ways we cannot diagnose the necrosis due exclusive to warfarin alone for reasons like the late onset and the characteristic histology picture. It couldn't be proper to define a sure etymologically CUA right only for the total histological lack of calcifications. In fact in several publications the typical histologically diagnosis was not confirmed or was unclear [3,6,44-46]. It is not particularly difficult distinguish the other pathologies causing skin necrosis thanks to very different immunological and/or microbiological triggering noxae, no showed clinical aspect of the progression phases except OAT calciphylaxis-like (Table 1). So it may be appropriate to redefine "calciphylaxis-like" the pathologies similar to the black necrotizing panniculitis or cellulitis. However, the fundamental therapeutic strategies that should never be overlooked irrespective of the cause of the necrotic lesion and/or calcification deposits. The main strategies have always to include: hanging as soon as possible OAT, use of sodium thiosulfate, particularly in view of its significant adjunctive vasodilatatory and antioxidant properties on the small vessels, mandatory treatment of protein-caloric malnutrition and use of an accurate calcium kinetic control and a

hard specific regenerative medication. Appropriate control of diabetes and smoking cessation should be always achieved. To conclude, oral anticoagulant therapy shouldn't be ever underestimated in front of all suspicious suspect skin lesions.

References

1. Cozzolino M, Brancaccio D, Gallieni M, Slatopolsky E. Pathogenesis of vascular calcification in chronic kidney disease. *Kidney Int.* 2005; 68: 429-436.
2. Schlieper G, Schurgers L, Brandenburg V, Reutelingsperger C, Floege J. Vascular calcification in chronic kidney disease: an update. *Nephrol Dial Transplant.* 2015; 31: 31–39.
3. Angelis M, Wong LL, Myers SA, Wong LM. Calciphylaxis in patients on hemodialysis: a prevalence study. *Surgery.* 1997; 122: 1083-1090.
4. Wilmer WA, Magro CM. Calciphylaxis: emerging concepts in prevention, diagnosis and treatment. *Semin Dial.* 2002; 15: 172-186.
5. Weenig RH, Sewell LD, Davis MD, McCarthy JT, Pittelkow MR. Calciphylaxis: natural history, risk factor analysis and outcome. *J Am Acad Dermatol.* 2007; 56: 569-579.
6. Mazhar Ar, Johnson RJ, Gillen D, Stivelman JC, Ryan MJ, Davis CL, et al. Risk factors and mortality associated with calciphylaxis in end stage renal disease. *Kidney Int.* 2001; 60: 324-332.
7. Budisavljevic MN, Cheek D, Ploth DW. Calciphylaxis in chronic renal failure. *J Am Soc Nephrol.* 1996; 7: 978-982.
8. Brandenburg VM, Kramann R, Specht P, Ketteler M. Calciphylaxis in CKD and beyond. *Nephrol Dial Transplant.* 2012; 27: 1314-1318.
9. Nigwekar SU, Kroshinsky D, Nazarian RM, Goverman J, Malhotra R, Jackson VA, et al. Calciphylaxis: Risk Factors, Diagnosis and Treatment. *Am J Kidney Dis.* 2015; 66: 133-146.
10. Brandenburg VM, Cozzolino M, Ketteler M. Calciphylaxis: a still unmet challenge. *J Nephrol.* 2011; 24: 142-148.
11. Guldbakke KK, Khachemoune A. Calciphylaxis. *Int J Dermatol.* 2007; 46: 231-238.
12. Cozzolino M, Mazzaferro S, Pugliese F, Brancaccio D. "Vascular calcification and uremia: what do we know?" *Am J Nephrol.* 2008; 28: 339-346.
13. Shmidt E, Murthy NS, Knudsen JM, Weenig RH, Jacobs MA, Starnes AM, et al. Net-like pattern of soft-tissue calcification on plain radiographs in patients with calciphylaxis. *J Am Acad Dermatol.* 2012; 67: 1296-1301.
14. Schafer C, Heiss A, Schwarz A, Westenfeld R, Ketteler M, Floege J, et al. The serum protein alpha 2-Heremans-Schmid glycoprotein/Fetuin-A is a systemically acting inhibitor of ectopic calcification. *J Clin Invest.* 2003; 112: 357-366.
15. Han MM, Pang J, Shinkai K, Franc B, Hawkins R, Aparicio CM. Calciphylaxis and bone scintigraphy: case report with histological confirmation and review of the literature. *Ann Nucl Med.* 2007; 21: 235-238.
16. Norris B, Vaysman V, Line BR. Bone scintigraphy of calciphylaxis: a syndrome of vascular calcification and skin necrosis. *Clin Nucl Med.* 2005; 30: 725-727.
17. Hayashi M. Calciphylaxis: diagnosis and clinical features. *Clin Exp Nephrol.* 2013; 17: 498-503.
18. KDIGO clinical practice guidelines for the diagnosis, evaluation, prevention and treatment of chronic kidney disease-mineral and bone disorder. *Kidney Int Suppl.* 2009; S1-130.
19. Janigan DT, Hirsch DJ, Klassen GA, MacDonald AS. Calcified subcutaneous arterioles with infarcts of the subcutis and skin ("calciphylaxis") in chronic renal failure. *Am J Kidney Dis.* 2000; 35: 588-597.

20. Stavros K, Motiwala R, Zhou L, Sejdiu F, Shin S. Calciphylaxis in a dialysis patient diagnosed by muscle biopsy. *J Clin Neuromuscul Dis.* 2014; 15: 108-111.
21. Latus J, Kimmel M, Ott G, Ting E, Alscher MD, Braun N. Early stages of calciphylaxis. Are skin biopsies the answer? *Case Rep Dermatol.* 2011; 3: 201-205.
22. Gotch FA, Levin N, Kotanko P. Calcium balance in dialysis is best managed by adjusting dialysate calcium guided by kinetic modeling of the relationship between calcium intake, dose of vitamin D analogues and the dialysate calcium concentration. *Blood Purif.* 2010; 29: 163-176.
23. Brandenburg V, Adragao T, van Dam B, Evenepoel P, Frazão JM, Ketteler M, et al. Blueprint for a European calciphylaxis registry initiative: the European Calciphylaxis Network (EuCalNet). *Clin Kidney J.* 2015; 8: 567-571.
24. Pasini E, Aquilani R, Dioguardi FS. "The enemy within". How to identify chronic diseases induced-protein metabolism impairment and its possible pharmacological treatment. *Pharmacol Res.* 2013; 76: 28-33.
25. Aquilani R. Oral amino acid administration in patients with diabetes mellitus: supplementation or metabolic therapy? *Am J Cardiol.* 2004; 93: 21A-22A.
26. Messner B, Bernhard D. Smoking and cardiovascular disease: mechanisms of endothelial dysfunction and early atherogenesis. *Arterioscler Thromb Vasc Biol.* 2014; 34: 509-515.
27. Brandenburg VM, Floege J, Ketteler M. Kalzifizierende urämische Arteriopathie. *Nephrologie.* 2009; 32: 67-74.
28. Cozzolino M, Brandenburg V. Warfarin: to use or not to use in chronic kidney disease patients? *J Nephrol.* 2010; 23: 648-652.
29. Danziger J. Vitamin K-dependent Proteins, Warfarin, and Vascular Calcification. *Clin J Am Soc Nephrol.* 2008; 3: 1504-1510.
30. Price PA, Caputo JM, Williamson MK. Bone origin of the serum complex of calcium, phosphate, fetuin, and matrix Gla protein: Biochemical evidence for the cancellous bone-remodeling compartment. *J Bone Mineral Res.* 2002; 17: 1171-1179.
31. Proudfoot D, Skepper JN, Hegyi L, Bennett MR, Shanahan CM, Weissberg PL. Apoptosis regulates human vascular calcification in vitro: evidence for initiation of vascular calcification by apoptotic bodies. *Circ Res.* 2000; 87: 1055-1062.
32. Krueger T, R Westenfeld, Schurgers LJ, Brandenburg V. Coagulation meets calcification: the vitamin K system. *Int J Artif Organs.* 2009; 32: 67-74.
33. Brandenburg VM, Cozzolino M, Mazzaferro S. Calcific uremic arteriopathy: a call for action. *Semin Nephrol.* 2014; 34: 641-647.
34. Knauf F, Chaknos CM, Berns JS, Perazella MA. Dabigatran and kidney disease: a bad combination. *Clin J Am Soc Nephrol.* 2013; 8: 1591-1597.
35. Bijarnia RK, Bachtler M, Chandak PG, van Goor H, Pasch A. Sodium Thiosulfate Ameliorates Oxidative Stress and Preserves Renal Function in Hyperoxaluric Rats. *PLOS One.* 2015; 10: e0124881.
36. Araya CE, Fennell RS, Neiberger RE, Dharnidharka VR. Sodium Thiosulfate Treatment for Calcific Uremic Arteriopathy in Children and Young Adults. *Clin J Am Soc Nephrol.* 2006; 1: 1161-1166.
37. Aquilani R, Zuccarelli GC, Dioguardi FS, Baiardi P, Frustaglia A, Rutili C, et al. Effects of oral amino acid supplementation on long-term-care-acquired infections in elderly patients. *Arch Gerontol Geriatr.* 2011; 52: e123-e128.
38. Roth E. Immune and cell modulation by amino acids. *Clin Nutr.* 2007; 26: 535-544.
39. Bolasco P, Caria S, Cupisti A, Secci R, Saverio Dioguardi F. A novel amino acids oral supplementation in hemodialysis patients: a pilot study. *Ren Fail.* 2011; 33: 1-5.
40. Sukkar SG, Gallo F, Borrini C, Vaccaro A, Marchello C, Boicelli R, et al. Effects of a new mixture of essential amino acids (Aminotrofic) in malnourished haemodialysis patients. *Med J Nutrition Metab.* 2012; 5: 259-266.
41. Leaper DJ, Schultz G, Carville K, Fletcher J, Swanson T, Drake R. Extending the TIME concept: what have we learned in the past 10 years? *Int Wound J.* 2012; 9: 1-19.
42. Ketteler M, Biggar PH. Evolving Calciphylaxis-What Randomized, Controlled Trials Can Contribute to the Capture of Rare Diseases. *Clin J Am Soc Nephrol.* 2015; 10: 726-728.
43. Shirashi N, Kitamura K, Miyoshi T, Adachi M, Kohda Y, Nonoguchi H, et al. Successful treatment of a patient with severe calcific uremic arteriopathy (Calciphylaxis) by etidronate disodium. *Am J Kidney Dis.* 2006; 48: 151-154.
44. Kranke P, Bennett MH, Martyn-St James M, Schnabel A, Debus SE, Weibel S, et al. Hyperbaric oxygen therapy for chronic wounds. *Cochrane Database Syst Rev.* 2015; 6: CD004123.
45. Zacharias JM, Fontaine B, Fine A. Calcium use increases risk of calciphylaxis: a case-control study. *Perit Dial Int.* 1999; 19: 248-252.
46. Hayashi M, Takamatsu I, Kanno Y, Yoshida T, Abe T, Sato Y, et al. A case-control study of calciphylaxis in Japanese end-stage renal disease patients. *Nephrol Dial Transplant.* 2012; 27: 1580-1584.